



Full length Research paper

Toxico-pathological changes and phytochemically-induced alleviation in Diabetic Rats Treated With *Gongronema latifolium* Leaf Extracts

Edet EE^{1*}, Edet TE³, Akpanabiatu MI², David-Oku E¹, Atangwho IJ¹, Igile G¹, Mgbeje B¹, and Uboh FE¹

¹Department of Biochemistry, University of Calabar, P.M.B. 1115, Calabar, Nigeria.

²Department of Biochemistry, University of Uyo, P.M.B. 1017, Uyo, Nigeria.

³Ministry of Water Resources, Calabar, Cross River State, Nigeria.

Abstract

This work assessed the effect of *Gongronema latifolium* Benth et Hook (Asclepiadaceae) leaf-extract on the histology of pancreas, kidney, heart and liver tissues of diabetic and non-diabetic male rats. The pancreas of diabetic rats which showed reduction in beta-cell density and size, distorted reticular support and infiltration of inflamed cells, recovered, showing distinct and highly populated beta- and alpha-cells upon treatment with 400mg/kg body wt extract. The renal tubules of the diabetic rat kidneys indicated inflammation and obscured borders between convoluted tubules. However, gavaging with the extract caused a restoration and regeneration of these hitherto inflamed cells. Hyperglycaemia as well as extract administration caused no significant change in the heart tissues within the period, except that the myocytes of the extract-treated rats were multinucleated and hypertrophied. No significant change was also observed in the histology of the liver. Result of phytochemical screening of leaf-extract revealed the presence of alkaloids, saponins, tannins, phlobatannins, cardiac glycosides, reducing sugars and polyphenols in both ethanol and aqueous extracts. However, polyphenols and saponins were relatively higher in ethanol extract compared to the aqueous. The possible regenerative, protective and restorative effect of extract against hyperglycaemia-induced tissue toxicity may be attributable to these phytochemicals.

Keywords: *Gongronema latifolium* leaf extract, hyperglycaemia, phytochemical screening, histological changes.

INTRODUCTION

The wet and dry forests of tropical Africa are endowed with abundant natural plant resources, with rich dietary and medicinal properties utilized locally in folk medicine (Dalziel, 1937). Some work have been documented on the nutritive/ medicinal properties of some tropical forest plants among which are: *Treculia africana*, (Edet *et al.*, 1985); *Portulaca oleracea*, (Parry *et al.*, 1987); *Ficus carica*, (Dominguez *et al.*, 1996); *Eleophorbia drupifera*, (Eno and Itam, 1996); *Piper guineense*, (Udoh and Akpan 1996); *Sacoglottis gabonensis*, (Udosen and Ujong 1998); *Tetracarpidium conophorum*, (Enujiugha, 2003);

Nauclea latifolia, (Akpanabiatu *et al.*, 2005), *Rauwolfia vomitoria* (Akpanabiatu *et al.*, 2006), and *Gongronema latifolium* (Edet *et al.*, 2011).

Despite these efforts, most of the existing plants are yet to be fully exploited for the benefit of the common man. *Gongronema latifolium* is one of the medicinal plants commonly used in our urban and rural communities in Nigeria, for the treatment of malaria, diabetes, hypertension, inflammation, stomach pains and various other ailments. Only the leafy portion of the plant is used medicinally, at present, for treatments of various ailments by traditional healers. The phytochemical composition of *Gongronema latifolium* reported to date are those of Ekundayo (1980) who identified from the petrol soxhlet extract of the stem, the presence of lupenyl cinnamate, lupenyl acetate, lupeol (lupenol) and β -

*Corresponding Author E-mail: emmaneffiongedet@yahoo.com

sistosterol. Some years later, Schneider et al. (1993) isolated from the chloroform extract of the leaves two pregnan-ester glycosides. Aside from these two analyses, report on the phytochemicals in GL is scanty in the literature and also discrepancies exist even among the few available.

Despite the long use of *Gongronema latifolium* in herbal medicine and its efficacy in the treatment of various ailments, particularly diabetes mellitus, little is known about the possible effect, either at short term or long term usage on the histological architecture of the cardinal tissues involved in metabolism, liver, heart, kidney and pancreatic tissues after alloxan necrotic damage. This study was designed therefore to evaluate the possible cytotoxic effect of GL on these tissues and also correlate these "effects"/changes if any, with the active phytochemical principles identified in *Gongronema latifolium* leaf extract in alloxan diabetic rat model.

MATERIAL AND METHODS

Preparation of crude leaf extract

Fresh leaves of *Gongronema latifolium* were obtained from villages in Akpabuyo local Government Area of Cross River State, Nigeria. Its identification and authentication/ certification were undertaken at the herbarium of Botany Department, University of Calabar, Nigeria. Water soluble fraction of the ethanol extract was prepared according to the procedure of Ugochukwu and Babady (2003) and used for this study.

Method of phytochemical screening

20g of the ground powdered sample was dissolved (by shaking) in 100mls of ethanol for 1 hr. The extract were refluxed in a flask twice for 30 min, filtered with a Whatman No. 1 filter paper and concentrated to 50ml. The extracts were used for the phytochemical tests according to the methods of Harborne, 1973:

Test for alkaloids

2ml of extract was stirred with 5ml of 1% aqueous hydrochloric acid on a steam bath for 30min; 1ml of the filtrate was treated with a few drops of Mayer's reagent and 1ml of a second portion was treated with Dragendorff's reagent. Turbidity or precipitation with either of the reagents was taken as preliminary evidence for the presence of alkaloids.

Test for saponins

The ability of saponins to produce frothing in aqueous

solution and to haemolyse red blood cells was used as a screening test for these compounds. About 0.5g of the extract was shaken with water in a test tube. Frothing which persisted for at least 30min on warming was taken as evidence for saponins (Harborne, 1973).

Test for tannins

2ml of extract was stirred with 10ml of distilled water and ferric chloride reagent was added to the filtrate. A blue-black, green or blue-green precipitate was taken as evidence for the presence of tannins.

Test for phlobatannins

2ml of the alcoholic aqueous extract was boiled with 5ml of 1% hydrochloric acid for 10 min. Deposition of a red precipitate was taken as the evidence for the presence of phlobatannins.

Test for anthraquinones

2ml of alcoholic/aqueous extract was shaken with 5ml of 10% ammonia solution added to the filtrate. The mixture was shaken and the presence of a pink, red to violet colour in the ammoniacal (lower) phase indicated the presence of anthraquinones.

Test for hydroxymethyl anthraquinones

2ml of alcoholic/ aqueous extract was treated with 5ml of 10% ammonia solution. The formation of a red colouration or precipitate indicated the presence of hydroxymethyl anthraquinones.

Test for cardiac glycosides

0.5g of each extract was dissolved in 2ml chloroform. Concentrated sulphuric acid was carefully added to it to form a lower layer; a reddish brown colour at the interface indicated the presence of a steroidal ring (aglycone portion of the cardiac glycoside).

Test for flavonoids

2ml of each extract was added to a few pieces of aluminum foil followed with concentrated hydrochloric acid. The formation of a crimson, red, orange or magenta colour was taken as evidence for the presence of flavonoids.

Table 1. Phytochemical screening of water and ethanol extracts of *Gongronema latifolium* leaves.

S/No.	Chemical constituents	Aqueous extract	Ethanol extract
I	Alkaloids	+	+
II	Anthraquinones	—	—
III	Hydroxy-methyl anthraquinones	—	—
IV	Cardiac Glycosides	+	+
V	Flavonoids	—	—
VI	Reducing sugars	+	+
VII	Polyphenols	++	+++
VIII	Phlobatannins	+	+
IX	Tannins	+	+
X	Saponins	+	++

KEY:

+	Present
++	Present in excess
+++	Present in much excess
—	Not detectable

Test for reducing sugars

To 2ml of the extract in a test tube was added 5ml of Fehlings solution and heated in a water bath for 10min. The formation of a brick-red precipitate or solution was taken as evidence for the presence of reducing compounds.

Test for polyphenols

To 2ml of extract was added 5 ml of distilled water and heated in a water bath for 30min. 1ml of Ferric chloride was added to the mixture followed by 1ml of 1% potassium ferricyanide. The formation of a green-blue colouration indicated the presence of polyphenols.

Animal treatments

Fifty-six mature male albino rats of the Wistar strain weighing 180-330g were obtained from the animal stock in the Department of Biochemistry, University of Calabar, Nigeria. The animals were housed in a well-ventilated experimental section of the animal house at room temperature and fed normal rat crow (Pfizer livestock Co. Ltd. Aba, Nigeria) as well as water *ad libitum*. The 56 male rats were divided into two major (diabetic and non-diabetic) sets/batches of 28 rats each. A set comprised of 4 groups (diabetic and non-diabetics) of 7 rats each along side with their respective diabetic and non diabetic controls. The diabetic set, was induced with diabetes by intraperitoneal injection of a single dose of 150 mg/kg body weight of alloxan to the rats after a 24 hr fast (Esmerino *et al.*, (1998). Diabetes was confirmed after 7

days in rats which showed fasting blood glucose (FBG) levels of > 300mg/dl with a glucometer (One-Touch, Basic). The animals in the control groups received distilled water only, while the test groups 1, 2, and 3 (both diabetic and non-diabetic) received 200, 300 and 400 mg/kg body weight of water soluble fraction of the ethanol extract of the GL respectively, once per day for two weeks (14 days).

Preparation of liver, kidney, heart and pancreatic tissues.

Twenty-four hours after the last administration, the animals were anaesthetized under chloroform fumes and were dissected. Liver, kidney, heart and pancreas tissues were removed from the animals and fixed in 10% buffered formalin, thereafter sectioned, mounted on glass slide and stained with Haematoxylin and Eosin preparatory for histological examination. The histopathological studies were done in the histology laboratory, Anatomy Department, College of Medical Sciences, University of Calabar, Nigeria.

Phytochemical screening

A total of ten (10) phytochemical principles were screened in the leaf of *Gongronema latifolium* (Table 1). Water and ethanol were the two solvents used for the screening. Whereas anthraquinones, hydroxymethyl anthraquinones and flavonoids were not detected in the two solvents; alkaloids, cardiac glycosides, polyphenols, saponins, tannins and phlobatannins were detected in both aqueous and ethanol solvents. Saponins and poly-

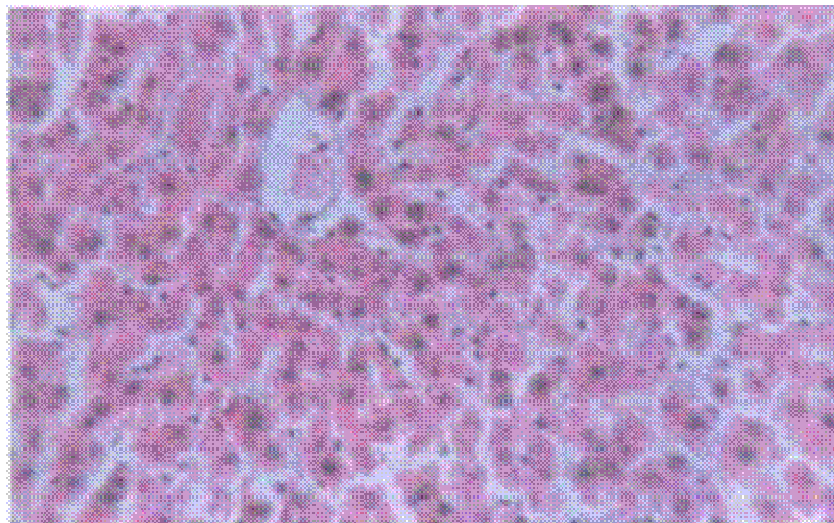


Figure 1a. Photomicrograph of a typical diabetic Liver section (mag x 100) of the treatment groups (2, 3 and 4) showing the hepatocytes radiating out, and within it are rounded open face nuclei smaller than those of the diabetic control.

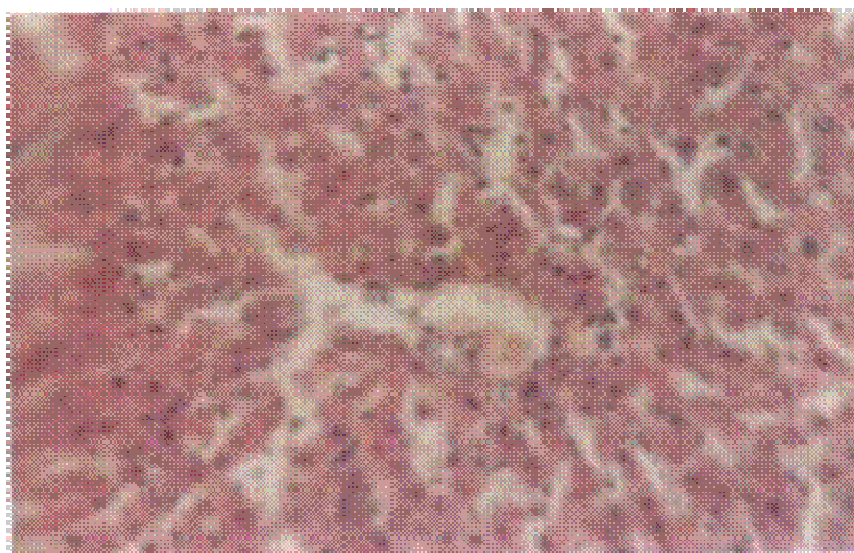


Figure 1b. Photomicrograph of a typical Liver section (mag x 100) of diabetic control group showing unaltered liver cell with numerous sinusoids, some wider while some are closely packed.

phenols were present in very appreciable quantities; moreover, these were detected more in ethanol than in the aqueous solvent.

RESULTS

The phytochemical screening of water and ethanol extracts of *Gongronema latifolium* leaves is shown in Table 1. Anthroquinones, hydroxymethyl anthraquinones and flavonoids were not detected in the two solvents,

while alkaloids, cardiac glycosides, polyphenols, saponins, tannins and phlobatannins were detected in both aqueous and ethanol solvents. Saponins and polyphenols were present in very appreciable quantities; however, they were detected more in ethanol than in the aqueous solvent.

Figure 1 shows the histology of the diabetic liver in treatment (a) compared to the diabetic control (b) and the non-diabetic control (c). Figure 2 shows the histology of the diabetic kidney in treatment (a) compared to the diabetic control (b) and the non-diabetic control (c).




Figure 1c. Photomicrograph of a typical Liver section (mag x 100) of non-diabetic control group showing normal liver cell with numerous sinusoids, some wider while some are closely packed.

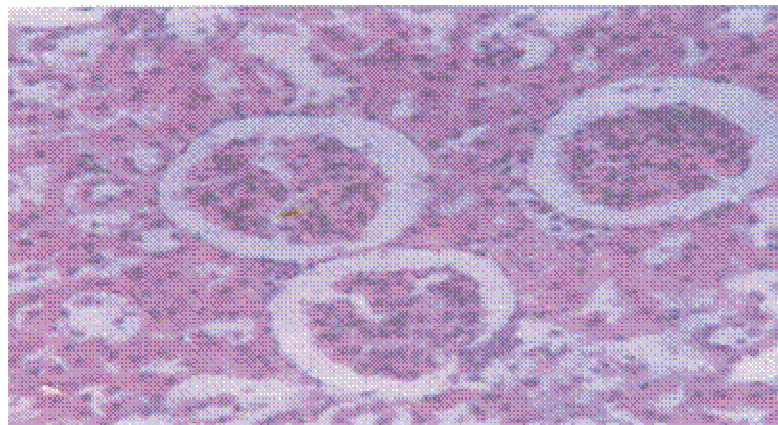


Figure 2a. Photomicrograph of a typical diabetic kidney section (mag x 100) of the treatment groups (2,3 & 4) showing shrunken glomeruli indicating degeneration of nuclei and increased Bowman's space. There were increased denudations of the tubules resulting in multinucleated parenchyma and degenerated juxtaglomeruli.

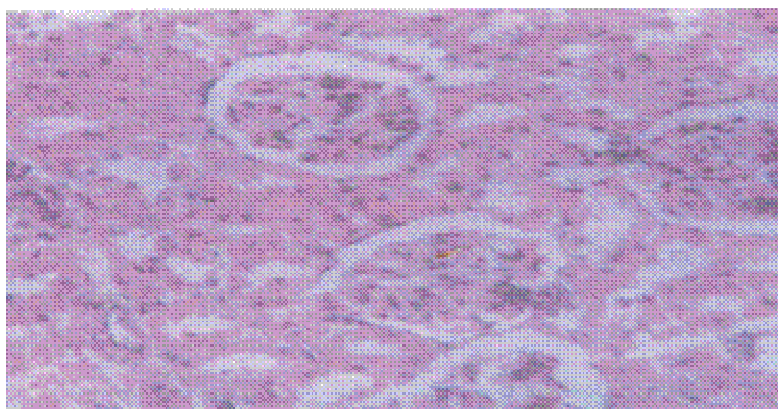


Figure 2b. Photomicrograph of a typical Kidney section (mag x 100) of diabetic control group showing larger renal capsules than the non-diabetic group. The epithelium of the convoluted tubules appears denuded obscuring the distinction between the proximal and distal convoluted tubules with early nephropathy.

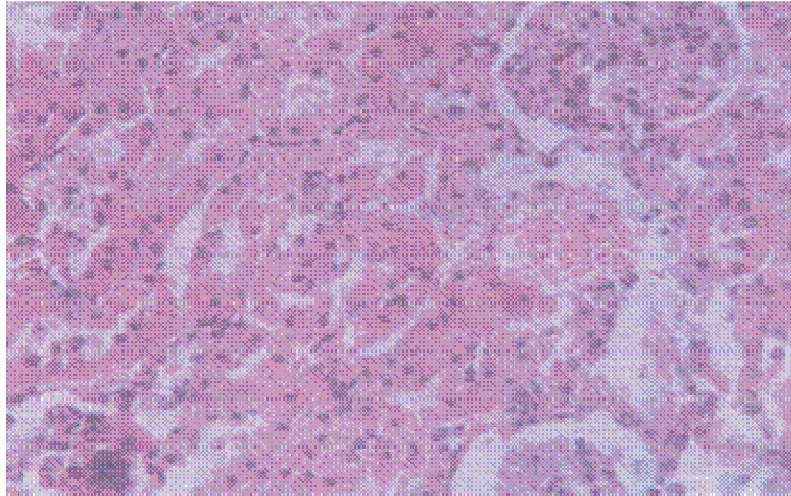


Figure 2c. Photomicrograph of a typical Kidney section (mag x 100) of non-diabetic control showing renal capsules with well distinct nuclei and intact Bowman's space epithelium. The tubules appear normal with largely distinct lumens.

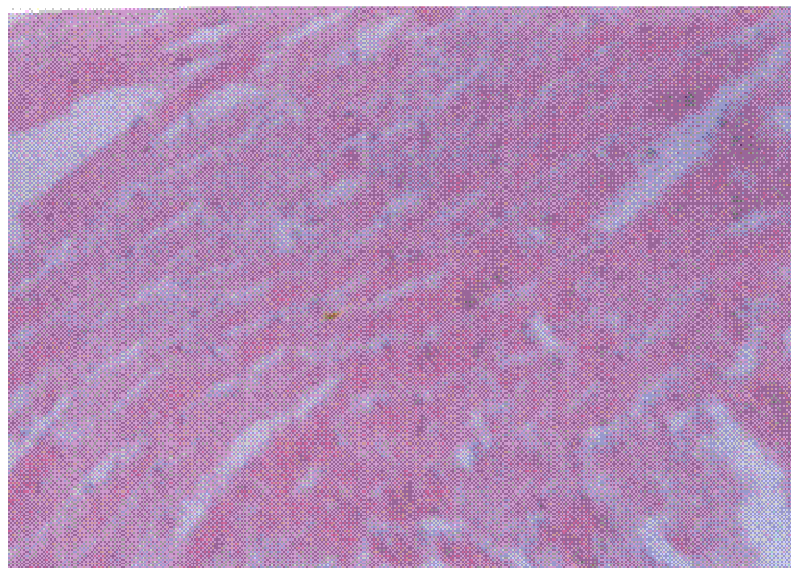


Figure 3a. Photomicrograph of a typical diabetic heart section (mag x 100) of the treatment groups (2,3 & 4) showing no alteration with the cytoarchitecture similar to that of normal control. The nuclei were centrally placed in the myocytes with interdigitation and intercalation.

Figure 3 shows the histology of the diabetic heart in treatment (a) compared to the diabetic control (b) and the non-diabetic control (c). Figure 4 shows the histology of the diabetic pancreas in treatment (a) compared to the diabetic control (b) and the non-diabetic control (c). The liver did not show any observable changes at all. The kidney showed the reappearance of new but few PCT and DCT, an indication of a slight healing effect. The diabetic heart showed no observable changes from the non-diabetic /normal, except that the myocytes were

thicker, multinucleated and hypertrophied. The pancreas showed the regeneration of distinct pancreatic islets with highly populated alpha and beta cells.

DISCUSSION

Toxicopathologic effect of alloxan on the pancreatic tissue revealed gross disappearance of β -cells from the pancreatic islets of diabetic control rats and a reduction in

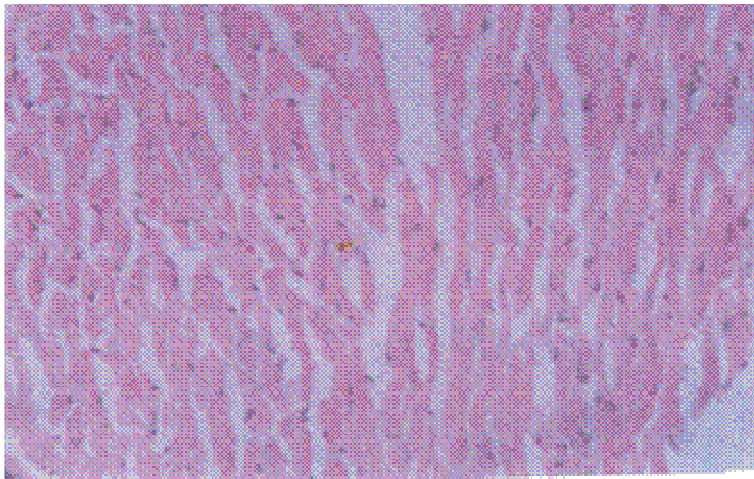


Figure 3b. showed Photomicrograph of a typical heart section (mag x 100) of diabetic control showing myocytes with their intercalated discs and interdigitations.




Figure 3c. Photomicrograph of a typical heart section (mag x 100) of non-diabetic control showing normal heart cell cytoarchitecture similar to that of the normal control.

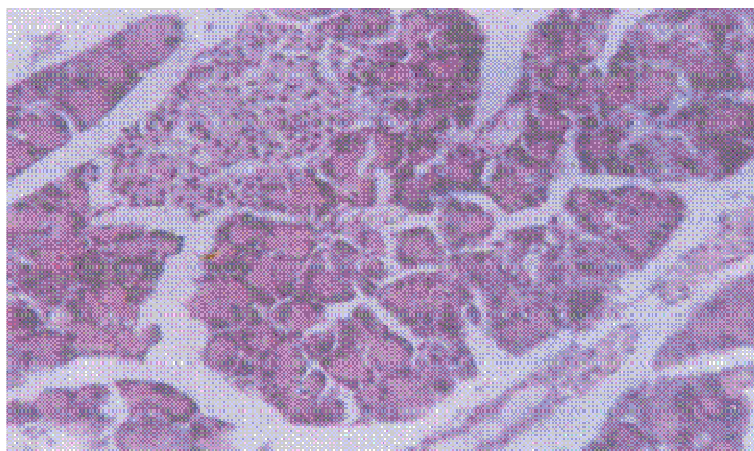


Figure 4a. Photomicrograph of a typical a typical diabetic pancreas section (mag x 100) of the treatment groups (2,3 & 4) showing distinct pancreatic cells with highly populated α and β cells.

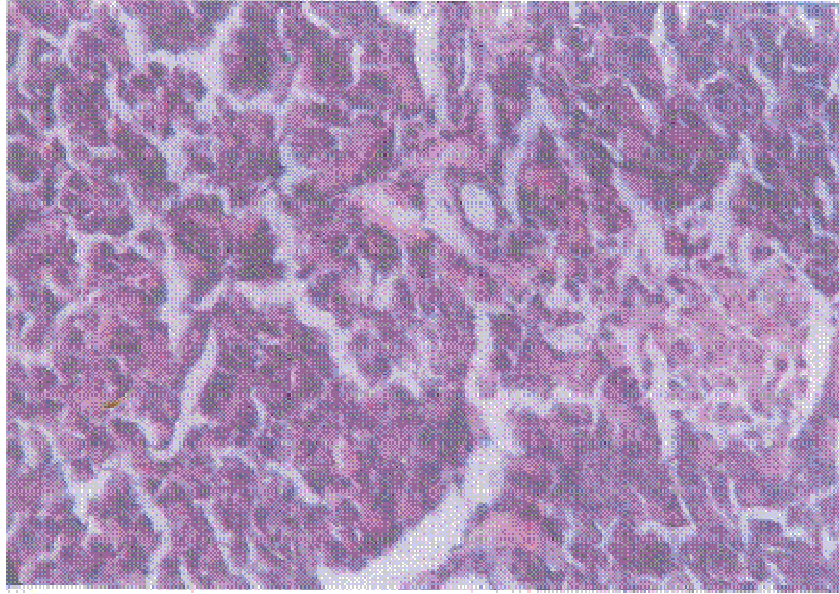


Figure 4b. Photomicrograph of a typical pancreas section (mag x 100) of diabetic control showing gross disappearance of the β -cell and reduction of the islets of Langerhans.

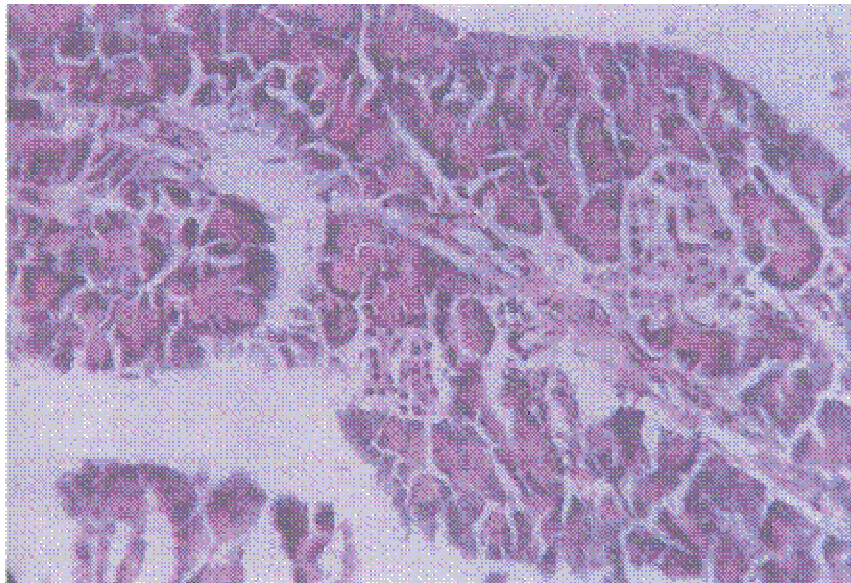


Figure 4c. Photomicrograph of a typical pancreas section (mag x 100) of non-diabetic control showing normal pancreas cell architecture.

the density of the islets. This indicated severe destruction of the β - (insulin secreting) cells in the islet of Langerhans. The reticular support of these cells was distorted, whereas, the peripherally placed alpha- (glucagon secreting) cells were distinct; while the δ -cells could not be differentiated from other cells. The infiltration of inflamed pancreatic cells in the islets was also observed. The diabetic rats treated with 200mg/kg body weight of the extract, showed reduced pancreatic islets

and few endocrine cells. However, at a test dose of 300 mg/kg body weight, the diabetic rats showed distinct pancreatic islets with highly populated alpha and beta cells. The diabetic rats gavaged with 400 mg/kg body weight of the extract, showed the presence of numerous distinct pancreatic islets which were larger than those of the non-diabetic rats treated with similar dose. The kidney tissue of diabetic control rats revealed renal capsules which were larger than that of non-diabetic rats.

Though distinct nuclei of cells of the glomerulus were present and the Bowman's space epithelium was intact, the epithelium of some of the convoluted tubules had been denuded obscuring the distinction between the proximal convoluted tubules (PCT) and distal convoluted tubules (DCT). Early nephropathic changes were observed. The juxtaglomerular apparatus were also outlined but the renal vessels were not. The diabetic rats gavaged with 200 mg/kg body weight of the extract showed shrunken glomerulus of the renal capsules indicating that there was a degeneration of the glomerulus, its cells and endothelium making the bowman's space larger; while the juxtaglomerulus appeared degenerated.

At a test dose of 300 mg/kg body weight of the extract, there was not much difference from observations in diabetic group II. Moreover, the PCT and DCT were still difficult to isolate because of the denudation. However, at a test dose of 400 mg/kg body weight of the extract, the diabetic rats showed the reappearance of new but few PCT and DCT; the juxta glomerular apparatus were slightly, though, no blood vessel could be identified in the renal interstitium; an indication of a slight healing effect. The myocytes of the heart tissue of diabetic control rats showed intercalated discs and interdigitation. The nucleus was centrally placed and no change was identified in the micrograph when compared to the non-diabetic rats. At a test dose of 200 mg/kg body weight, the heart of the diabetic rats showed no alteration from the non-diabetic rats. Treatment with 300 mg/kg body weight of leaf extract, showed no observable changes from the non-diabetic rats except that the myocytes were hypertrophied showing intercalated discs and interdigitation. The diabetic rats gavaged with 400 mg/kg body weight of leaf extract showed thicker, multinucleated and hypertrophied cardiac myocytes. The liver of diabetic control rats showed the lobule with the central vein from which radiated out in hexagonal pattern the hepatocytes. Within the hepatocytes were seen giant rounded nuclei; between the hepatocytes were numerous, closely packed sinusoids. The gavaging of diabetic rats with 200 mg/kg body weight of the extract showed rounded open-faced nuclei within the hepatocytes; the nuclei were not as large as those of the diabetic control group. Treatment with 300 mg/kg body weight of the extract showed the hepatocytes still radiated out in hexagonal pattern; the cells were stained eosinophilic more than the diabetic group II; within the hepatocytes, were the rounded open-faced nuclei well stained basophilic; the nuclei were smaller than those of the diabetic control. Between the hepatocytes the radially /closely-packed sinusoids were similar to those of the diabetic group II. Treatment of the diabetic rats with 400 mg/kg body weight of the extract showed hepatocytes in similar conditions to those of diabetic group III, except that some hepatocytes had two nuclei between them and the sinusoids were as observed in the control.

Observations of toxico-pathologic conditions depicted through the photomicrographs in the study revealed that the kidney and the pancreas were tissues hurt most by the toxic action of alloxan. The heart muscles showed some thickness and became hypertrophied with increased treatment of the extract. The liver did not seem to be hurt at all. Both the kidney and pancreatic tissues experienced some healing and regeneration following increased oral treatment with the extract. The alkaloids detected in the leaf extract may have significant role to play in numerous medical application of this herb. Phytochemicals can inhibit carcinogenesis by induction of phase II enzymes while inhibiting phase I enzymes, scavenge DNA reactive agents, suppress the abnormal proliferation of early pre-neoplastic lesions and inhibit certain properties of the cancer cell (Enstrom, 1999). Alkaloids have been shown to inhibit drug metabolic enzymes (Chen *et al.*, 1994) and such inhibition may terminate the biotransformation of drugs into active metabolites hence, limiting poisonous effects. Glycosides were identified as a component of *Gongronema latifolium* leaf extract and it is not known whether cardiac glycosides found in plants extracts are possible sources of human toxicity. Cardiac glycosides have vagotonic effects resulting in bradycardia and heart block. Cardiac glycosides which primarily affect cardiovascular, neurologic and gastro-intestinal systems are most significant. Glycosides have been reported to be involved in hepatoprotective effect of *Verbena officinalis* in experimental liver damage (Singh *et al.*, 1998). The undetectable levels of flavonoids, a naturally occurring phytochemical with confirmed antioxidant properties and potential cardioprotective effect in the phytochemical screen did not nullify the cardioprotective status of the herb. Polyphenols (simple phenols, flavonoids and tannins) were found in considerable quantity and may account for the cardioprotective effects of *Gongronema latifolium* leaf extract. It has been shown that phenols inhibit the oxidation of LDL (Renaud and de Lorgeril, 1992). Polyphenols are also known to have, in addition to antioxidant effect on LDL, other cardioprotective effects such as inhibition of platelet aggregation and vascular relaxation through the production of nitric oxide (Hertog *et al.*, 1993a). Polyphenols are also present in a number of fruits and vegetables (Ferro-Luzzi & Serratini, 1995). A number of studies have touted the potential benefits of consuming diets rich in fruits and vegetables (Bravo, 1998; Hertog *et al.*, 1993b). It has been reported that the attenuation of coronary heart disease risk in wine drinkers is probably due to as much as possible the lifestyles and consumption of high amounts of polyphenol containing fruits and vegetables as wine (Frankel *et al.*, 1995). It is likely that polyphenols in this herb may act as dietary antioxidant and so collectively bestow protection from the development of heart disease (Frankel *et al.*, 1995). The leaf of *Gongronema latifolium* may possess some phytochemical principles which could influence

amelioration, healing, protection and possibly the regeneration of necrosed rat body tissues against the toxico-pathologic effect associated with alloxan diabetogenesis.

In conclusion, experimental evidence was provided to show that the toxicity and morbidity conditions in diabetic rats following alloxan induction could be loss in weight from another report Edet *et al.*, 2011, liver, heart, kidney and pancreatic tissue targeted. The investigation also revealed that *Gongronema latifolium* leaf extract possessed some bioactive phytochemical principles which exerted dose-dependent effects on some body tissues of diabetic rats and could influence healing, amelioration, protection and regeneration but could not reverse the diabetic condition. From the fore-going, it is evident that various chemical ingredients of *Gongronema latifolium* leaf are capable of imparting on it some phytotherapeutic benefits; hence therein lay the facts for its healing potentials by our forebears and herbal medical practitioners in Nigeria.

REFERENCES

- Akpanabiatu MI, Umoh IB, Edet EE, Udosen EU, Udoh AE (2005). Rat serum electrolytes, lipid profile and cardiovascular activity on *Nauclea latifolia* leaf extract administration. *Ind. J. Clin. Biochem.* 20 (2):29-34.
- Akpanabiatu MI, Umoh IB, Eyong EU, Edet EE, Uboh FE (2006). Influence of *Rauwolfia vomitoria* root bark extract on cardiac enzymes of normal albino rats. *Recent Progress in Medicinal Plants Biopharmaceuticals* 14 (13): 297 – 304.
- Bravo L (1998). Polyphenols: chemistry, dietary sources, metabolism and nutritional significance, *Nutr. Rev.*, 56: 317-333.
- Chen M, Treadler TG, Christensen SB, Hviid L, Zhai L, Kharazmi A (1994). Licochaione A, a new antimalarial agent, inhibits in vitro growth of human malaria parasite *Plasmodium falciparum* and protects mice from *P. yoeli* infection. *Antimicrobial agents Chemother* 38: 1470-1475.
- Dominguez EJ, Canal R, Torres MD, Campillo JE, Perez C (1996). Hypolipidaemic activity of *Ficus carica* leaf extract in streptozotocin-diabetic rats. *Phytother Res* 10:526-528.
- Edet EE, Akpanabiatu MI, Uboh FE, Edet TE, Eno AE, Itam EH, Umoh IB (2011). *Gongronema latifolium* crude leaf extract reverses alterations in Haematological indices and weight-loss in Diabetic rats. *J. Pharmacol. Toxicol.* 6 (2): 174 –181.
- Edet EE, Eka OU, Ikon ET (1985). Chemical evaluation of the nutritive value of seeds of African Breadfruit *Treulia africana* *Food Chem.* 17: 41-47.
- Ekundayo O (1980). Constituents of *Gongronema latifolium* Benth Hook (*Asclepiadaceae*) *Quart. J. Crude Drug Res.* 3: 127-129.
- Eno AE, Itam E (1996). Hypoglycaemic agent(s) in leaves of *Eleophorbia drupifera*. *Phytother Res.* 10:680-682.
- Enstrom JE (1999). Smoking cessation and mortality trends among two US populations. *J. Clin. Epidemiol.* 52:813.
- Enujiugha VN (2003). Chemical and functional characteristics of conophor nut. *Pakistan J. Nutr.* 2(6):335-338.
- Esmerino LA, Ranali R, Rodriguer Jnr LA (1998). Blood glucose determination of normal and alloxan diabetic rats after administration of local anaesthetics containing vasoconstrictors. *Braz. Dent. J.* 9(1):33-37.
- Ferro-Luzzi A, Serrhini M (1995). Polyphenols in our diet: do they matter? *Nutrition* 11: 399-400.
- Frankel EN, Waterhouse AL, Teissedre PL (1995). Principal phenolic phytochemicals in selected California wines and their antioxidant activity in inhibiting oxidation of human low-density lipoproteins. *J. Agric. Food Chem.* 43: 890-894.
- Harborne JB (1973). *Phytochemical methods*. A guide to modern techniques of plant analysis. New York: Chapman and Hall. P. 25-88.
- Hertog MG, Hollman PC, Katan MB, Krumbout D (1993b). Intake of potentially anticarcinogenic flavonoids and other determinants in adults in the Netherlands, *Nutr. Cancer*, 20: 21- 29.
- Hertog MMG, Feskens EJ, Hollman PC, Katan MB, Krumbout D (1993a). Dietary antioxidant of flavonoids and risk of coronary heart disease: the Zutphen elderly study. *Lancet* 324: 1007-1011.
- Parry O, Okwukasaba FK, Ejike C (1987). Skeletal muscle relaxant action of an aqueous extract of *Portulaca oleracea* in the rat. *J. Ethnopharmacol.* 19: 247-253.
- Renaud SS, De Lorgeril M (1992). Wine, Alcohol, platelets and the French paradox for coronary heart disease. *Lancet*, 339(8808):1523-1526.
- Schneider C, Rotscheidt K, Breitmaier E (1993). Four new pregnane glycosides from *Gongronema latifolium* (Asclepiadaceae). *J. Prak Chemie* 335 (6):532-536.
- Singh B, Saxena A, Chandran BK, Anand KK, Suri OP, Suri KA, Satti KA (1998). Hepatoprotective activity of Verbenalin on experimental liver damage in rodents. *Fitoterapia* 69: 135-140.
- Udoh FV, Akpan JO (1996). Effects of leaf and root extract of *Piper guineense* on smooth muscle activity in rat, guinea pig and rabbit. *Phytother Res* 10:596-599.
- Udosen EO, Ujong AS (1998). Hepatotoxic activity of *Sacoglottis gabonensis* in rats. *Pharm Biol* 36: 368- 371.
- Ugochukwu NH, Babady NE (2003). Antihyperglycaemic effect of aqueous and ethanolic extracts of *Gongronema latifolium* leaves on glucose and glycogen metabolism in livers of normal and streptozotocin-induced diabetic rats. *Life Sci.* 73 (15): 1925-1938.