

Full Length Research Paper

Long-term changes in graft height after sinus floor augmentation with mesenchymal stem cells in a randomised clinical trial: radiographic evaluation with a minimum follow-up of 2.5 years

¹Niels Ulrich Hermund , ²Ole Donatsky, ³Henrik Nielsen, ⁴Christian Clausen, ⁵Palle Holmstrup

¹Consultant, Department of Oral and Maxillofacial Surgery, Rigshospitalet/Hilleroed Hospital, Copenhagen University Hospital, Denmark and Department of Periodontology, School of Dentistry, University of Copenhagen, Denmark
²Consultant, Department of Oral and Maxillofacial Surgery, Rigshospitalet/ HilleroedHospital, Copenhagen University Hospital, Denmark. ³Consultant, Department of Oral and Maxillofacial Surgery, Rigshospitalet unit Hilleroed, Copenhagen University Hospital, Denmark. ⁴Interface Biotech A/S, Hoersholm, Denmark. ⁵Professor, Department of Periodontology, School of Dentistry, University of Copenhagen, Denmark.

*Corresponding Author E-mail: nuhermund@hotmail.com

Abstract

To compare the changes in graft height in patients after sinus floor augmentation (SFA) with and without mesenchymal stem cells (MSCs) and to evaluate the survival rate of implants placed after SFA. **Material and methods:** Twenty patients were randomised into two groups. The test group patients had a bone biopsy taken from the tuberosity region from which bone cells were cultured. All patients had a SFA with a composite bone graft (BioOss[®]/autogenous bone). The patients in the test group had the cultured cells added. Two implants were placed in the augmented area four months later and the augmentation height at the distal side of the implants was evaluated from panoramic radiographs at the time of implant placement (T1) and after a minimum of 2.5 years (T2). The implant survival was evaluated. Due to insufficient bone quality one implant could not be placed 4 months after SFA, two implants disintegrated after prosthetic treatment and two implants in one patient were unaccounted for since the patient failed to show up – all in the MSC group. A statistically significant reduction in augmentation height of 1.27 ± 0.23 mm and 1.88 ± 0.37 mm in the MSC and non-MSC group was found after a minimum of 2.5 years, respectively ($p < 0.01$). No overall difference between the two groups was found ($p = 0.18$), however significantly less reduction in augmentation height was found in the most anterior implant position in the MSC group compared to the non-MSC group ($p < 0.05$). Adding MSCs to SFA did not improve implant survival after a minimum of 2.5 years. A reduction in augmentation height of 10-13 % was found. The anterior augmentation height was more stable when MSCs were added to the bone graft.

Keywords: Cultured cells, mesenchymal stem cells, dental implant, sinus floor augmentation, randomised clinical trial, radiographic evaluation.

Abbreviations

AB: Autogenous bone; DBBM: Deproteinized bovine bone material; MSC: Mesenchymal stem cell; PRP: Platelet-rich plasma; SFA: Sinus floor augmentation

INTRODUCTION

For many years bone loss in the posterior part of the maxilla has been treated by using autogenous bone and various bone substitutes (Jensen and Sennerby,

1998, Valentini et al., 1998). Among these materials “the gold standard” has so far been considered to be autogenous bone, primarily due to its resorption and replacement capacity (Becker et al., 1996). However, the

voluminous stability of sinus floor augmentations (SFA) over time is limited (Block et al., 1998, Boyne and James, 1980, Froum et al., 2006, Hallman et al., 2002) hereby necessitating larger augmentations for later implant placement. Longitudinal changes of the size of the augmentation and periimplant bone resorption can be visually demonstrated on panoramic radiographs. In meta-analyses (Del et al., 2004b, Esposito et al., 2010) it has been suggested that bone-substitute materials are as effective as autogenous bone when used alone or in combination with autogenous bone in terms of implant survival. Unfortunately limited amounts of autogenous bone is available intra-orally. Therefore, when larger amounts of autogenous bone are needed, grafts from the iliac crest may be necessary. This technique includes donor site morbidity up to 26 % of the patients (Silber et al., 2003). Reinert et al. (Reinert et al., 2003) demonstrated that in 30 patients treated with autogenous onlay and inlay bone and later insertion of all together 200 implants, a mean bone loss of 1.3 mm during the first year after bone grafting and only minimal resorption during the second and third year was observed. 7 implants out of 200 failed to integrate and further 4 implants were lost during follow-up.

In a retrospective quantitative radiographic analysis Geurs et al. (Geurs et al., 2001) demonstrated that maintenance of bone height was significantly improved in intraoral autogenous grafts versus allografts ($p < 0.05$).

Studies using different study designs, radiographic methods (Hallman et al., 2002, Ozyuvaci et al., 2003, Reinert et al., 2003, Zijdeveld et al., 2009) and grafting materials have been published in recent years. However, none of these have focused on tissue-engineering.

Tissue-engineering offers a potential to reduce the need for autogenous bone, thereby minimizing morbidity associated with bone harvesting. In a 2-6 year follow-up study Yamada et al. (Yamada et al., 2008) demonstrated that in 16 SFA procedures, injected tissue-engineered bone along with bone marrow-derived stromal cells and platelet-rich plasma (PRP) and simultaneous placement of dental implants, resulted in osseointegration of all 41 implants. The height of mineralized tissue after 2 years showed mean increases of 8.8 +/- 1.6 mm compared to preoperative values, and no adverse effects or remarkable bone resorption were seen during the 2-6-year follow-up time, however no control group was used. Our group has previously in detail characterized human primary bone cell cultures obtained from the tuberosity region and found that cells cultured from this region are composed of both mature osteoblasts and osteoprogenitor cells (Clausen et al., 2006a). The short term clinical and histological results of the present study have previously been described (Hermund et al., 2011). We now hypothesize that bone loss could be substituted by autogenous bone chips, deproteinized bovine bone

material (DBBM) and cultured bone cells / mesenchymal stem cells (MSCs) and that a composite graft with MSCs will show less reduction in augmentation height over time compared to composite grafts without MSCs.

The aim of the present study was 1) to evaluate the survival rate of implants placed in SFA consisting of DBBM + autogenous bone with and without MSCs; 2) to compare the changes in augmentation height with and without MSCs after a minimum of 2.5 years.

MATERIAL AND METHODS

Patients

Figure 1 presents an overview of the study design by means of the Consort explanatory flowchart. Twenty consecutive patients (11 women and nine men), with a mean age of 59.5 years (SD=9.65, range 40-77), treated over a period of 1.5 years were included in the study. This sample size was chosen based on a power calculation accepting a power of 88%, a significance of 5% and the arbitrary assumption that a clinically significant difference between treatments, would be a smaller change in sinus floor augmentation height from 25% in the control group to 10% in the test group (www.statpages.org). All patients were referred by their private dentists to the Department of Oral and Maxillofacial Surgery, Rigshospitalet/Hilleroed Hospital, Denmark because of unilateral Cawood class 5 atrophy of the posterior maxilla (Cawood and Howell, 1988) and the remaining alveolar crest having a height of less than 3 mm. The patients were verbally and in writing informed about the trial and given one week to evaluate the information before signing a consent form. The patients were randomised into two groups according to grafting method by the first- or the second author. The randomisation was conducted by a blinded draw from a bag containing 20 identical pieces of paper with the group name printed on them. All patients were partially edentulous with free end clinical situations distal to the first or second premolar.

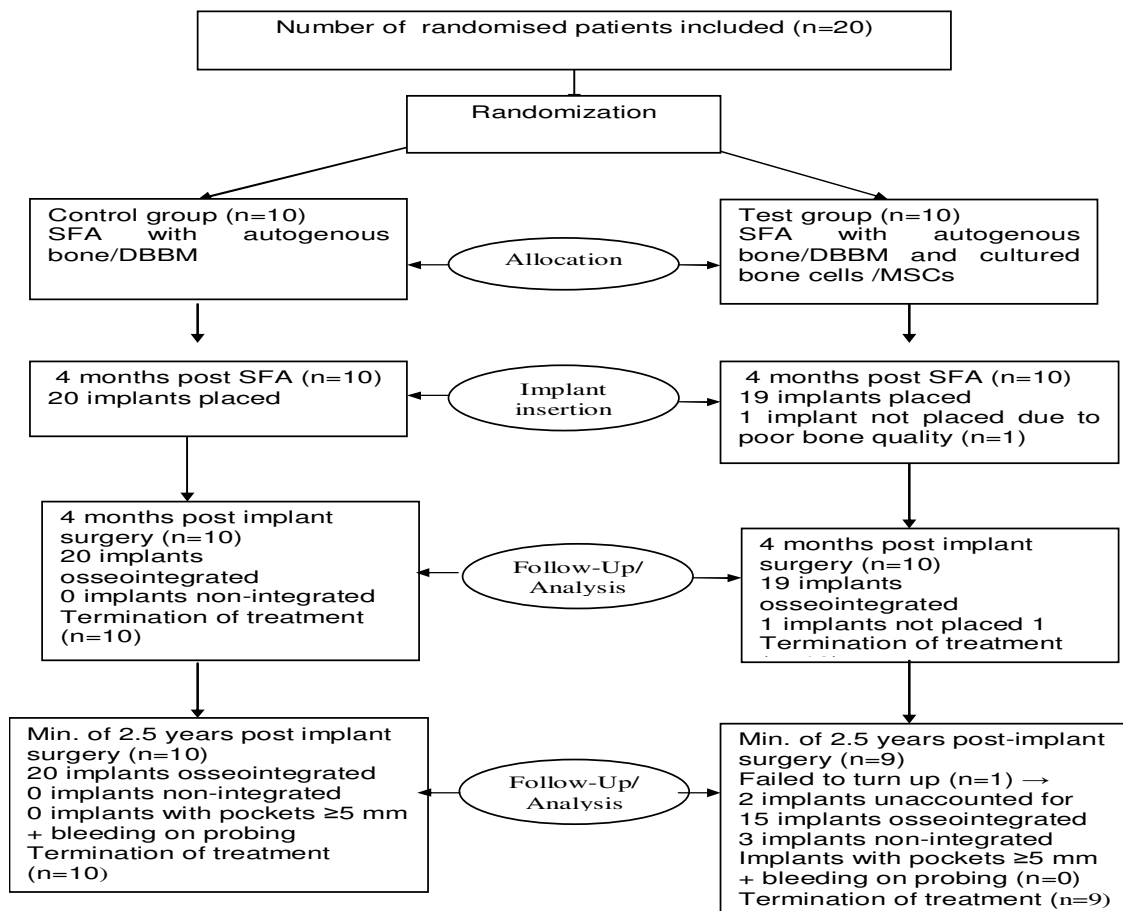
Exclusion criteria were:

- 1) Systemic disease (e.g. uncontrolled diabetes, autoimmune diseases, immunosuppressive chemotherapy)
- 2) History of chronic sinus infection and/or sinus surgery (e.g. Luc-Caldwell procedure)

The study was approved by the Local Ethics Board (2004-1-03).

Bone biopsy technique and in vitro culturing of MSCs

In the test group the patients had a bone biopsy taken under local anaesthesia from the atrophic tuberosity



region. Immediately afterwards the biopsy was stored in a transport medium containing Dulbeccos Modified Eagles Medium; Nutrient Mixture F12 (DMEM:F12) with fungizone (2.4g/ml) and Gentamycin (10mg/ml) (Both Invitrogen A/S, Taastrup, Denmark).

Also, a blood sample of 30 ml was taken from the antebrachium vein for use in the cell culturing procedure. The 10 patients in the control group did not have a bone biopsy nor a blood sample taken.

Bone cells were isolated, cultured and expanded as described previously by our group (Clausen et al., 2006b, Clausen et al., 2006a).

Sinus floor augmentation (SFA) procedure

All patients had a lateral maxillary fenestration and a lift of the Schneiderian membrane under local anaesthesia. Cranially, medially and laterally the space between the alveolar crest and the lifted sinus membrane was covered by a resorbable membrane (Bio-Gide Perio, Geistlich Biomaterials AG) and then augmented with a composite graft of 1 cm³ of autogenous bone harvested with a scraper (Safescraper®, Meta, Reggio Emilia, Italy) from the lateral side of the maxilla and 1 cm³ of DBBM

(BioOss®, Geistlich Biomaterials AG, Wohlhusen, Switzerland). In the cell group the MSCs were added to the composite graft prior to augmentation, while the patients in the control group had no cells added. Wound closure was performed with Ethicon silk sutures (Johnson & Johnson, USA) and removed one week later. To prevent postoperative infection all patients received penicillin V (1 g three times daily) for one week starting after the operation.

Implant placement

After 4 months of healing two dental implants (4,1 mm diameter or Wide Neck, length 10-12mm Plus, Straumann SLA dental implant, Institute Straumann AG, Basel, Switzerland) were placed in each patient. The bone preparation was performed by a trephine bur in order to harvest bone samples, which allowed for later histologic examination of the augmentation area (Hermund et al., 2011). Wound closure was performed with Ethicon silk sutures (Johnson & Johnson, USA) and removed after 1 week.

A total of 39 Straumann dental implants were placed with a length of 10- or 12 mm depending on the height of

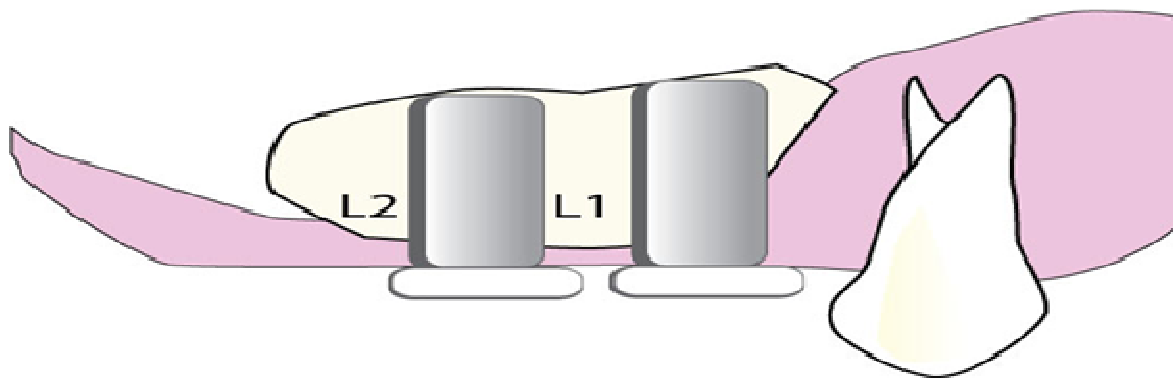


Figure 2. Measurements were performed at two locations: L1: distally of the most anterior implant at the first bone to implant contact. L2: distally of the most posterior implant at the first bone to implant contact.

the augmentation. In the cell group one patient only had one implant placed due to insufficient bone quality after SFA.

Radiographic examinations

From the time of the first examination to the last follow-up examination (range 33-52 months) five panoramic radiographs were taken: at the first clinical examination, after sinus floor augmentation, after implant placement, after implant placement (T1) and at the follow-up examination after a minimum of 2.5 years (T2). The panoramic radiographs at T1 and T2 were used for morphometric electronic calibrated measurements distally of both implants from the first bone to implant contact to the most cranial part of the augmentation (Figure 2). The distal implant position was chosen to minimize measurement flaws. To eliminate the influence of marginal bone loss, the distance between the shoulder of the implant and the marginal bone level was measured at T1 and T2, and if any increase in height occurred, the difference was subtracted. The assessors were the first author and a radiologist both of whom were blinded to patient group allocation.

The panoramic radiographs were all taken using a Planmeca Cephalostat OYPN 2002 CC (Planmeca, Helsinki, Finland). Graft height was measured using the calibrated soft-ware system Centricity (GE Healthcare, Glostrup, Denmark). The software allows input of a conversion factor so that the augmentation height was expressed directly in millimeters. The height was measured to the nearest 0.01 mm. The augmentation measurements were reproduced in a pilot study to 0.02 mm.

Prosthetic treatment

All 20 patients were examined clinically and radiographi-

cally 4 months after placement of the dental implants. At the same time standardized abutments were placed leaving 2-3 mm space to the opposing tooth. The final prosthetic treatment was performed by the patients' private dentist. The final treatment including crowns were clinically examined and approved by the first- or the second author.

Clinical evaluation after a minimum of 2.5 years after implant placement

All patients were recalled and clinically examined by the first author who was blinded to the patient group allocation. Implant stability by percussion, pockets around the implants and the occlusion of the crowns were evaluated. If the implant pocket depth exceeded 5 mm and bleeding on probing was found, the patient was referred to the private dentist for treatment of peri-implantitis.

Statistical method

Comparisons between the two groups regarding the height of SFA were performed with the non-parametric Mann-Whitney test and Welch Two Sample t-test, while the reproducibility of the measurements was tested using the Wilcoxon signed-rank test. The level of significance was set to $p \leq 0.05$; the Statistical Analysis Software (SAS) 9.1 (SAS Institute Inc., Cary, NC, USA) for Windows was used for the calculations.

RESULTS

There was no difference in gender- and age distribution of the participants (Table 1). The panoramic radiographs at T1 and T2 were taken at a mean of 7.7 months (range: 7-9) after the clinical examination and 34.75 months after

Table 1. Distribution of patient age and sex according to sinus floor augmentation

	Without MSCs (n=10)	With MSCs (n=10)
Mean age (SD)	58.5 (8.1)	60.4 (11.2)
Men, number	5	4
Women, number	5	6

Table 2. Time (months) (and SD) from clinical examination to the time of implant placement (T1) and from implant placement to height evaluation (T2), according to sinus floor augmentation.

	n	Mean
T1 Without MSCs	10	7.6 (± 0.70)
T1 With MSCs	10	7.8 (± 0.63)
T2 Without MSCs	10	37.0 (± 5.10)
T2 With MSCs	9	36.11 (± 5.40)

Table 3. Mean changes (\pm SE) in augmentation height over a minimum of 2.5 years according to sinus floor augmentation.

	Mean change \pm standard error (mm)
Without MSCs, n=10	-1.88 \pm 0.37
With MSCs, n=9	-1.27 \pm 0.23

implant placement (range: 27-46), respectively (Table 2). One patient in the cell group failed to show up for follow-up examination despite several recall attempts. This patient's implant status was therefore unaccounted for and hence excluded from the trial.

There was no statistically significant difference in time of radiographic examination (T1 and T2) between the two groups ($t=0.67$, $df=18$, $p=0.51$; $t=0.37$, $df=17$, $p=0.72$, respectively).

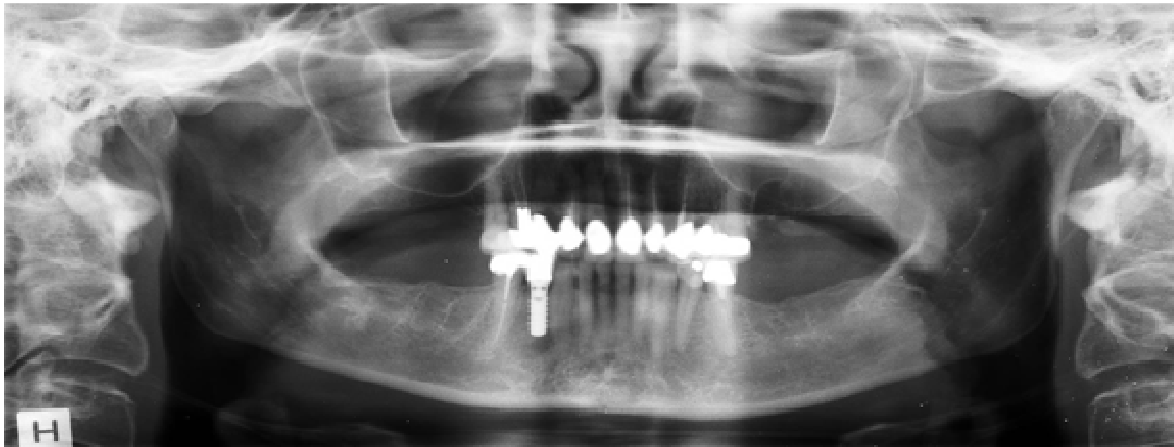
A statistically significant mean reduction in augmentation height from T1 to T2 of 13 % and 10 % in the non-cell group versus the cell group, respectively was found ($p<0.01$) (Table 3). There was no statistically significant difference in augmentation height reduction

(anterior and posterior position combined) between the two groups ($p=0.18$). However, a significantly smaller mean augmentation reduction in the most anterior implant position in the cell group was found ($p<0.05$). In the most posterior implant position no significant difference in augmentation height was found ($p=0.50$) (Table 4).

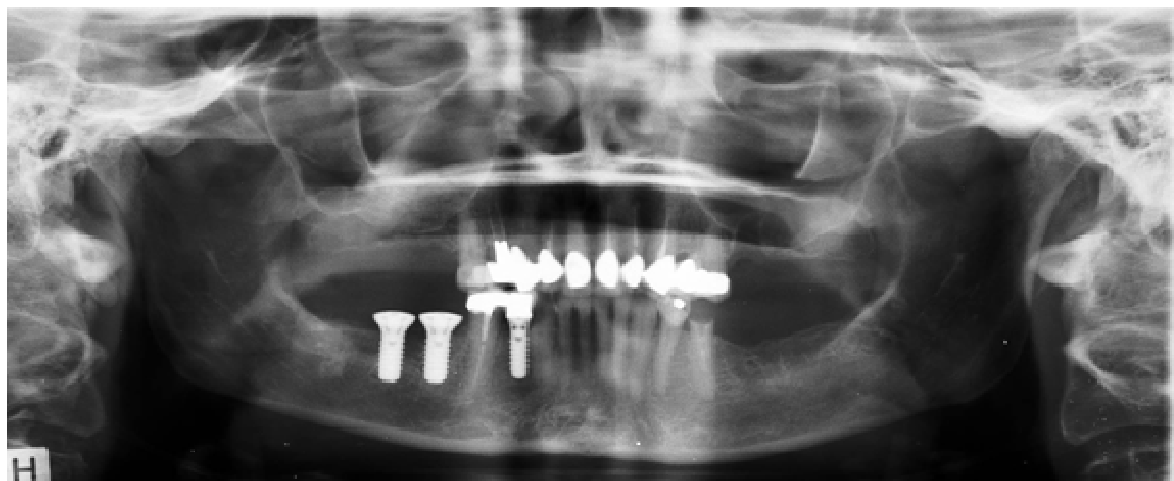It was impossible to place one implant due to insufficient bone quality and further two patients had non-osseointegration of the most posterior implant shortly after having prosthetic treatment. These implants were all placed in the cell group. All remaining implants were still well-integrated and with pockets <5 mm and with no bleeding on probing after a minimum of 2.5 years (Figure 3).

Table 4. Changes in augmentation height (\pm SE) distally of two implants according to sinus floor augmentation.

	Anterior implant	Posterior implant
	Mean, mm (\pm SE)	Mean, mm (\pm SE)
Without MSCs, n=10	-2.39 (\pm 0.76)	-1,37 (\pm 0.80)
With MSCs, n=9	-0,94 (\pm 0.46)	-1.69 (\pm 0.77)



A

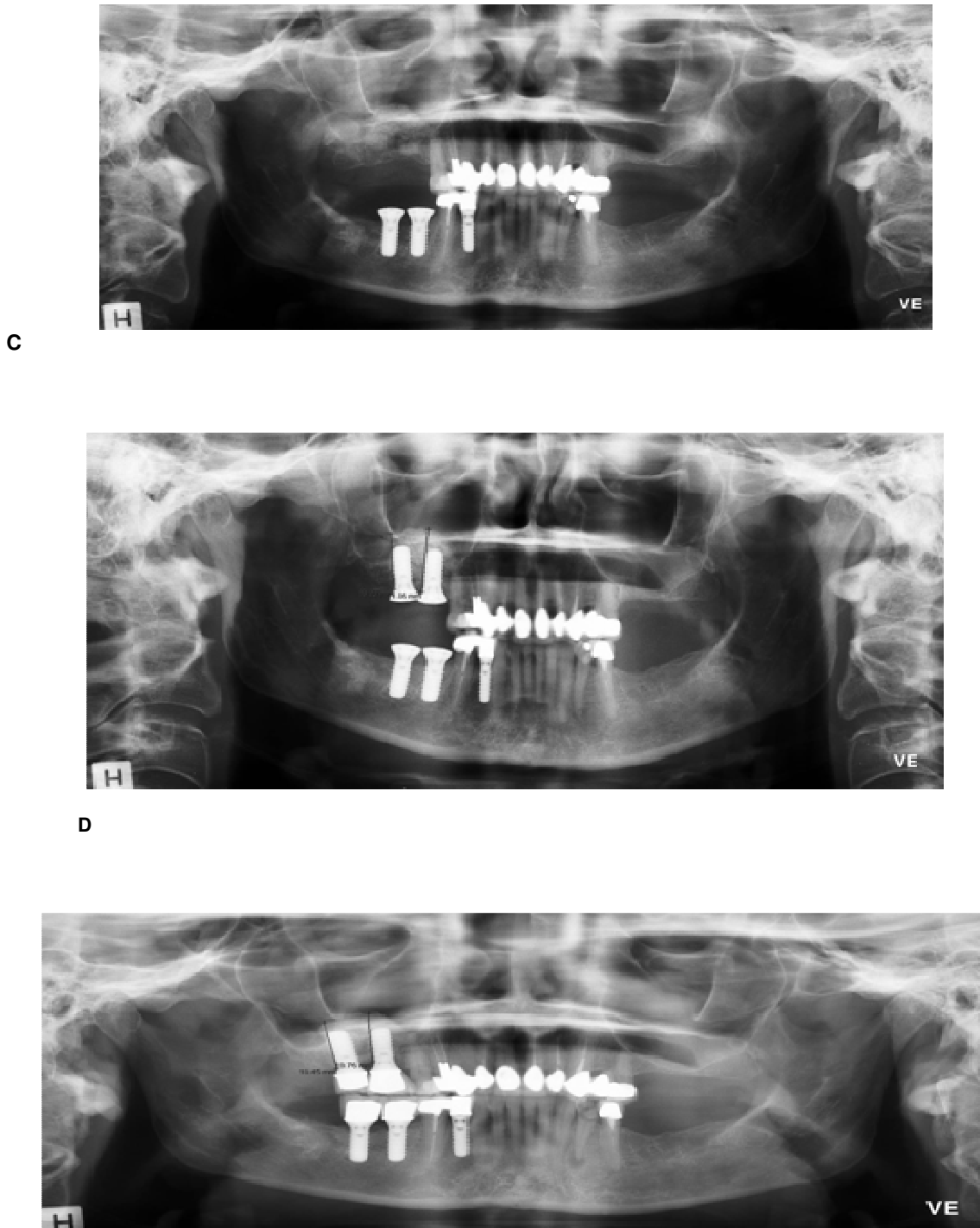


B

DISCUSSION

In the present study, the long term changes in augmentation height after SFA were radiographically assessed in a randomized clinical trial using DBBM and autogenous bone and in the test group with the addition of MSCs. SFA has been extensively described with different materials (Block et al., 1998, Chaushu et al.,

2009, Del et al., 2004a, Esposito et al., 2010, Meyer et al., 2009, Ozyuvaci et al., 2003, Velich et al., 2004, Zijderveld et al., 2009). We found a statistically significant reduction in augmentation height over time of 10 % with MSCs and 13 % without MSCs, which is in accordance with most of these studies, depending on bone grafting material. At the more anterior implant position a significantly smaller loss in augmentation height was found in the group with



E
Figure 3. (A) Panoramic radiograph of a 40-year old woman with Cawood class 5 atrophy of the posterior part of the maxillary processus on the right side. (B) Panoramic radiograph after SFA on the right side. (C) Panoramic radiograph before implant placement 4 months after SFA. The patients private dentist placed two implants on the right side of the mandibel. D) Panoramic radiograph after implant placement (T1). E) Panoramic radiograph 34 months after implant placement (T2). Measurements distally of implants is noted at D) and E).

MSCs than in the group without ($P < 0.05$). No previous studies addressing the long term changes in SFA including

MSCs have so far been published. The difference in augmentation height found more anteriorly could indicate

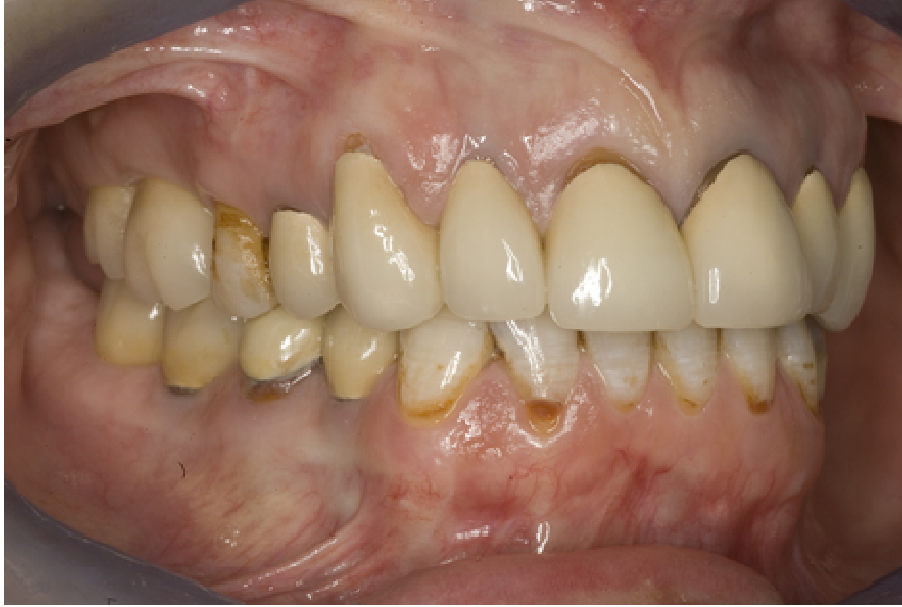

Figure 4. Clinical situation 34 months after implant placement. Implants 17 and 16 are clinically osseointegrated and with no pockets exceeding 5 mm nor bleeding on probing. The occlusion of the crowns were found to be excellent.

less resorption in the group *with* MSCs due to the ability to condensate the composite graft more densely thereby creating a tighter scaffold which could increase the number of bone producing cells. In the more posterior position the condensation of the composite graft is looser, thereby creating a more porous structure, which may allow less bone producing cells to adhere and therefore no statistically significant difference between the two groups was found. Two implants disintegrated after prosthetic treatment and one implant could not be placed due to insufficient bone quality. This could indicate that MSCs in combination with SFA with DBBM and autogenous bone actually decreases implant survival. However, the small number of patients included makes the result uncertain. Furthermore, the smoking habits of the patients were unaccounted for in the present study. Studies have demonstrated the influence of tobacco (Levin et al., 2005, Snider et al., 2011) and future studies should therefore if possible only include non-smokers or at least have an evenly distributed number of smokers in the study groups.

The present study was for economic reasons limited to 20 patients, which means that a difference in augmentation height and implant survival between the two groups could be present, but not detectable. A larger number of patients would have to be included in order to measure a statistically significant difference.

The vertical height of the augmentation was measured on panoramic radiographs. The radiographs will provide a 2-dimensional picture of a 3-dimensional situation. Projection phenomena can therefore occur, limiting the precision of the measurements. For ethical reasons it

was not possible to obtain permission to perform CT-scans, which could potentially be more precise. Cone beam CT scanning was at the time of the trial not available at the hospital. On the other hand Ozyuvaci et al. (Ozyuvaci et al., 2003) found no statistically significant difference in augmentation height between the panoramic radiographs and the CT.

Cell cultivation procedures allowed a cell concentration of 2×10^6 /ml. It is possible that a higher cell concentration could positively alter the height of the augmentation. Furthermore, the cell suspension was liquid and could therefore flow to non-augmented areas. This could lower the cell concentration in the augmented area. A higher viscosity might result in a higher cell concentration in the augmented area and thereby minimizing the loss in augmentation height. Ultimately, a postponed application of the MSCs to the augmentation could improve the nutritional conditions for the MSCs as suggested by Meijer et al (Meijer et al., 2007).

By using the present method, it is unknown whether the present bone reflects newly formed bone or residual bone from the grafting. Further murine studies using radioactive and degradative bone could produce evidence of this aspect.

In the present study a barrier resorbable membrane was used study to cover the lateral fenestration to the sinus cavity. In a study using DBBM for SFA, Wallace et al. (Wallace et al., 2005) concluded that vital bone formation was found in 17.6%, 16.9%, and 12.1%, respectively, for the Bio-Gide, Gore-Tex, and no membrane groups. Of the 135 implants placed, three implants disintegrated (two in the Bio-Gide group, one in

the Gore-Tex group). There was no significant difference between the membrane groups as to vital bone formation and implant survival. At present no data regarding the stability of the augmentation height with regard to the use of a membrane over the lateral fenestration, is available.

In a previous preliminary report Schmelzeisen et al. (Schmelzeisen et al., 2003) suggested the possibility to place implants in bone reconstructed with cultured bone cells in humans. However, the maxillary bone atrophy was limited and therefore the results are not comparable with the results in the present study, in which the maxillary atrophy was more severe (< 3 mm pristine bone present).

Ideally, complete resorption of the bone substitute and replacement by autogenous bone is preferable, since the bone to implant contact will be enhanced, thereby increasing the level of osseointegration. However, too fast resorption is undesirable since this can cause limited bone volumes for later dental placement (Artzi et al., 2004). The results of the present study regarding the augmentation height was partly due to non-resorption of DBBM, which was also demonstrated by Mordenfeld et al. (Mordenfeld A., 2009) in a 11-years follow-up study in eleven patients including histologic examination in which no resorption of the DBBM particles was found. Likewise Valentini et al. (Valentini et al., 1998) found no visible signs of resorption of the DBBM particles one year after SFA.

The decrease in augmentation height over the first three years was also found by other authors (Reinert et al., 2003, Velich et al., 2004, Zijdeveld et al., 2009). Zijdeveld et al. found a statistically significant reduction in augmentation height over time in all locations after SFA with autogenous bone and β -tricalcium phosphate.

The time required to obtain optimal bone formation after SFA can be from 6 to 9 months or even longer with grafting materials other than autogenous bone. To minimize the time for sufficient bone formation a SFA technique with a bone substitute and MSCs would be preferable. McAllister et al. (McAllister et al., 2009) demonstrated in a series of 5 patients that MSCs added to a bone substitute accelerated bone maturing and resulted in a bone volume of 33%. Unfortunately no data on the augmentation height in this study was presented.

At present it is still not clear which bone substitute should be used and which bone cell concentration should be applied to obtain significant improvement compared to a SFA without MSCs.

There is a need for new randomised clinical trials, in which the cell concentration is increased and/or the carrier is changed and/or the recipient site is changed i.e. onlays. A postponed MSC approach could be nutritional beneficial. Furthermore, much larger sample sizes are needed.

CONCLUSIONS

Adding MSCs to SFA consisting of DBBM and AB does not improve implant survival after a minimum of 2.5 years. SFA with and without MSCs resulted in a radiographic augmentation reduction of 10 % and 13 %, respectively over the same period, however a statistically significant smaller augmentation reduction was found in the cell group in the most anterior implant position.

ACKNOWLEDGEMENTS

Funding for the study was provided by Hilleroed Public Hospital, Capital Region, Denmark. Dr. Clausen is an employ of Interface Biotech SA, Denmark. There is no other conflict of interest.

REFERENCE

- Artzi Z, Weinreb M, Givol N, Rohrer MD, Nemcovsky CE, Prasad HS, Tal H (2004). Biomaterial resorption rate and healing site morphology of inorganic bovine bone and beta-tricalcium phosphate in the canine: a 24-month longitudinal histologic study and morphometric analysis. *Int J Oral Maxillofac Implants* (19): 357-368.
- Becker W, Urist M, Becker BE, Jackson W, Parry DA, Bartold M, Vincenzzi G, De GD, Niederwanger M (1996). Clinical and histologic observations of sites implanted with intraoral autologous bone grafts or allografts. 15 human case reports. *J Periodontol* (67): 1025-1033.
- Block MS, Kent JN, Kallukaran FU, Thunthy K, Weinberg R (1998). Bone maintenance 5 to 10 years after sinus grafting. *J Oral Maxillofac Surg* (56): 706-714.
- Boyne PJ, James RA (1980). Grafting of the maxillary sinus floor with autogenous marrow and bone. *J Oral Surg* (38): 613-616.
- Cawood JI, Howell RA (1988). A classification of the edentulous jaws. *Int J Oral Maxillofac Surg* (17): 232-236.
- Chaushu G, Mardinger O, Calderon S, Moses O, Nissan J (2009). The use of cancellous block allograft for sinus floor augmentation with simultaneous implant placement in the posterior atrophic maxilla. *J Periodontol* (80): 422-428.
- Clausen C, Hermund NU, Donatsky O, Nielsen H (2006a). Characterization of human bone cells derived from the maxillary alveolar ridge. *Clin Oral Implants Res* (17): 533-540.
- Clausen C, Hermund NU, Donatsky O, Nielsen H, Osther K (2006b). Homologous activated platelets stimulate differentiation and proliferation of primary human bone cells. *Cells Tissues Organs* (184): 68-75.
- Del F M, Testori T, Francetti L, Weinstein R. (2004a). Systematic review of survival rates for implants placed in the grafted maxillary sinus. *Int J Periodontics Restorative Dent* (24): 565-577.
- Del F M, Testori T, Francetti L, Weinstein R. (2004b). Systematic review of survival rates for implants placed in the grafted maxillary sinus. *Int J Periodontics Restorative Dent*; (24): 565-577.
- Esposito M, Grusovin M G, Rees J, Karasoulos D, Felice P, Alissa R, Worthington H, Coulthard P (2010). Effectiveness of sinus lift procedures for dental implant rehabilitation: a Cochrane systematic review. *Eur J Oral Implantol* (3): 7-26.
- Froum S J, Wallace S S, Elian N, Cho S C, Tarnow D P (2006). Comparison of mineralized cancellous bone allograft (Puros) and inorganic bovine bone matrix (Bio-Oss) for sinus augmentation:

- histomorphometry at 26 to 32 weeks after grafting. *Int J Periodontics Restorative Dent* (26): 543-551.
- Geurs N C, Wang I C, Shulman L B, Jeffcoat M K (2001). Retrospective radiographic analysis of sinus graft and implant placement procedures from the Academy of Osseointegration Consensus Conference on Sinus Grafts. *Int J Periodontics Restorative Dent* (21): 517-523.
- Hallman M, Hedin M, Sennerby L, Lundgren S. A (2002). prospective 1-year clinical and radiographic study of implants placed after maxillary sinus floor augmentation with bovine hydroxyapatite and autogenous bone. *J Oral Maxillofac Surg* (60): 277-284.
- Hermund N U, Stavropoulos A, Donatsky O, Nielsen H, Clausen C, Reibel J, Pakkenberg B, Holmstrup P. (2011). Reimplantation of cultivated human bone cells from the posterior maxilla for sinus floor augmentation. Histological results from a randomized controlled clinical trial. *Clin Oral Implants Res*.
- Jensen O T, Sennerby L.(1998). Histologic analysis of clinically retrieved titanium microimplants placed in conjunction with maxillary sinus floor augmentation. *Int J Oral Maxillofac Implants* (13): 513-521.
- Levin L, Schwartz-Arad D, Nitzan D. [Smoking as a risk factor for dental implants and implant-related surgery]. *Refuat Hapeh Vehashinayim* 2005; (22): 37-43, 85.
- McAllister B S, Haghighat K, Gonshor A (2009). Histologic evaluation of a stem cell-based sinus-augmentation procedure. *J Periodontol* (80): 679-686.
- Meijer G J, de Bruijn J D, Koole R, van Blitterswijk C A. Cell-based bone tissue engineering. *PLoS Med* 2007; (4): e9.
- Meyer C, Chatelain B, Benarroch M, Garnier J F, Ricbourg B, Camponovo T (2009). (Massive sinus-lift procedures with beta-tricalcium phosphate: long-term results). *Rev Stomatol Chir Maxillofac* (110): 69-75.
- Mordenfeld A (2009). Histological analysis of biopsies harvested 11 years after sinus floor augmentation with an 80 : 20 mixture of deproteinized bovine and autogenous bone. Hallman M, Johansson C, and Albrektsson T. *Clin.Oral Implants.Res.* 20(9), 863-864.
- Ozyuvaci H, Bilgic B, Firatli E (2003). Radiologic and histomorphometric evaluation of maxillary sinus grafting with alloplastic graft materials. *J Periodontol* (74): 909-915.
- Ref Type: Generic
- Reinert S, Konig S, Bremerich A, Eufinger H, Krimmel M (2003). Stability of bone grafting and placement of implants in the severely atrophic maxilla. *Br J Oral Maxillofac Surg* (41): 249-255.
- Schmelzeisen R, Schimming R, Sittlinger M (2003). Making bone: implant insertion into tissue-engineered bone for maxillary sinus floor augmentation-a preliminary report. *J Craniomaxillofac Surg* (31): 34-39.
- Silber J S, Anderson D G, Daffner S D, Brislin B T, Leland J M, Hilibrand A S, Vaccaro A R, Albert T J (2003). Donor site morbidity after anterior iliac crest bone harvest for single-level anterior cervical discectomy and fusion. *Spine* (28): 134-139.
- Snider T N, Cottrell D, Batal H (2011). Summary of current consensus on the effect of smoking on implant therapy. *J Mass Dent Soc* (59): 20-22.
- Valentini P, Abensur D, Densari D, Graziani J N, Hammerle C. Histological evaluation of Bio-Oss in a 2-stage sinus floor elevation and implantation procedure. A human case report. *Clin Oral Implants Res* 1998; (9): 59-64.
- Velich N, Nemeth Z, Toth C, Szabo G (2004). Long-term results with different bone substitutes used for sinus floor elevation. *J Craniofac Surg* (15): 38-41.
- Wallace S S, Froum S J, Cho S C, Elian N, Monteiro D, Kim B S, Tarnow D P (2005). Sinus augmentation utilizing anorganic bovine bone (Bio-Oss) with absorbable and nonabsorbable membranes placed over the lateral window: histomorphometric and clinical analyses. *Int J Periodontics Restorative Dent* (25): 551-559.
- Yamada Y, Nakamura S, Ito K, Kohgo T, Hibi H, Nagasaka T, Ueda M (2008). Injectable tissue-engineered bone using autogenous bone marrow-derived stromal cells for maxillary sinus augmentation: clinical application report from a 2-6-year follow-up. *Tissue Eng Part A* (14): 1699-1707.
- Zijderveld S A, Schulten E A, Aartman I H, ten Bruggenkate C M (2009). Long-term changes in graft height after maxillary sinus floor elevation with different grafting materials: radiographic evaluation with a minimum follow-up of 4.5 years. *Clin Oral Implants Res* (20): 691-700.