

Full Length Research Paper

Evaluating the cross-sectional area (CSA) of the median nerve by ultrasound in carpal tunnel syndrome (CTS)

Boontaree Wanitwattananurug^{1*}, Vithya Varavithya¹, Woraphon Aramrussameekul²

¹Department of Radiology, Faculty of Medicine, HRH Princess Maha Chakri Sirindhorn Medical Center, Srinakharinwirot University, Ongkharak, Nakhon Nayok, Thailand.

²Department of Orthopaedic, Faculty of Medicine, HRH Princess Maha Chakri Sirindhorn Medical Center, Srinakharinwirot University, Ongkharak, Nakhon Nayok, Thailand.

Accepted 13 July, 2011

This study is carried out to evaluate the diagnostic value of ultrasound (US) of the median nerve in carpal tunnel syndrome (CTS) in Thai patients. CTS patients and asymptomatic control subjects were examined, and the median nerve with Ultrasound (US) and underwent a nerve conductive studies (NCS). A linear array transducer was used to scan and measure the median nerve cross-sectional area (CSA). This data was compared to previous NCS results. There were twenty-three CTS patients, in whom 34 wrists were diagnosed as CTS, and 60 wrists in 30 asymptomatic controls. CSA calculated by the tracing method (TM) and ellipsoid formula (EF) methods was found to be significantly lower in the study group than in the controls ($p < 0.001$). Thus, quantitative assessment of the median nerve provides an accurate diagnostic test (TM; sensitivity 85.29% and specificity 90.28%, EF; sensitivity of 70.59%, specificity 87.50%), with an area larger than 9 mm² being highly predictive. High sensitivity and specificity of quantitative US assessment in the diagnosis of CTS were confirmed in the patients, when compared with NCS. There was no difference in the US cut-off value of the median nerve between the Thai population and the others.

Keywords: Cross-sectional area of median nerve, ultrasound, carpal tunnel syndrome.

INTRODUCTION

Carpal tunnel syndrome (CTS) is one of the most common upper limb compression neuropathies (Atroshi et al., 1999; Patterson and Simmons, 2002). It is due to an entrapment of the median nerve within the carpal tunnel. There are many causes of CTS including the narrowing of the carpal tunnel space, from inflammation, trauma, degeneration, osseous compression, vascular compression and tumors. One of the common precipitating factors of CTS is occupational health conditions, particularly in industries where work involves high pressures and repetitive use of vibrating tools. Diagnosis is usually being made clinically combined with nerve conductive studies (NCS) (Aroori and Spence, 2008). Recently, magnetic resonance imaging (MRI) and ultrasound (US) are choices for subsequent investigation (Allmann et al., 1997; Chen et al., 1997; Wiesler et al., 2006; Duncan et al., 1999). The advantages of the ultra-

sound are non-invasive in nature and it does not cause any discomfort or pain when compared with NCS. It has potential advantages of being widely available, has a relatively lower cost and shorter examination times than MRI.

The objective of this study was to evaluate the diagnostic value of US on the median nerve in CTS patients, to evaluate the cut-off value for the CSA in Thai patients and compare the mean values of CSA in Thai population.

MATERIALS AND METHODS

This prospective study was approved by the ethics committee of Faculty of Medicine, Srinakharinwirot University and conducted during September, 2009 to May 2010 Participants signed the informed consent form prior their enrollments.

Ultrasound was evaluated CSA in asymptomatic subjects and CTS patients. All CTS patients had characteristic clinical symptoms and physical examinations

*Corresponding author E-mail: boontaree_@hotmail.com

Table 1. Demographic data in the study and the control groups

	Control group	Study group
Age	38.40 ± 6.27 years	46.92± 7.97 years
Sex		
men	15	9
women	15	14
BMI	23.87 ± 5.17 kg/m ²	25.47 ± 4.83 kg/m ²
Hand		
Right dominant	28	19
Left dominant	2	4

consisted with the syndrome. These cases underwent NCS within 2 weeks prior or after ultrasound with positive results. The control subjects were healthy volunteers with no clinical signs or symptoms of CTS. All control subjects were screened to exclude systemic disorders such as diabetes mellitus, connective tissue disorders, and kidney or thyroid abnormalities. Occupational health conditions, particularly in industries where work involved high force and repetitive use of vibrating tools were excluded. Another exclusions included previous wrist surgery, existing anatomic variations in the median nerve, CTS symptoms secondary to other neurological causes, space occupying lesions, and pregnancy. All of these subjects underwent NCS.

Demographic data were collected for gender, age, weight, height, occupation, and determination of the dominate hand in the patient data.

The collected data were analyzed using R software program. The demographic data were presented as means ± standard deviation.

Ultrasound protocol

High-resolution ultrasound using a 12 MHZ linear transducer was conducted to scan all wrists in a neutral position with palms up and fingers in a semi-extended position. The course of the median nerve was assessed in transverse planes.

The CSA of median nerve was measured by two different methods as suggested by Duncan and co-workers (Duncan et al., 1999). The first method was the direct measurement, using the tracing method (TM), in which the margin of median nerve was measured with electronic calipers. This measurement was performed from the inner border of the perineural, echogenic rim surrounding the hypo echoic median nerve as shown in figures 1a and 2a. The second method was an indirect measurement, using an ellipsoid formula (EF), calculating the transverse and antero-posterior dimensions. In this measurement, the formula of ellipsoid area was used $D1 \times D2 \times 3.14/4$ as shown in figures 1b and 2b. For each wrist, the measurements were repeated three times and

the average of these three values were taken. The ultrasound images were recorded in CD.

RESULTS

There were 30 asymptomatic, healthy subjects (the control group) and 23 CTS subjects (the study group). The median nerve was clearly defined in all subjects.

The control group

NCS and US of median nerves of wrist measurements were performed bilaterally in all controls. The number of control cases was 30 (15 men, 15 women) and their mean age was 38.40 ± 6.27 years (range 30-53). The mean of BMI in this group was 23.87 ± 5.17 kg/m² (table1).

Mean CSA as calculated by TM was 6.87 ± 0.93 mm² (range 5.33-9.00). Mean CSA as calculated by EF was 6.80 ± 0.99 mm² (range 5.00-9.24). No significant differentiation was observed between CSA calculated by TM and EF of median nerve (p= 0.419).

There was no significant difference in CSA between men and women by TM and EF methods. No significant difference in any measurements were found in the dominate and the non-dominate hand. (p=0.702 and p=0.774, respectively).

The study group

There were 23 patients (9 men, 14 women), whose 34 wrists were NCS diagnosed as CTS. The remaining 12 wrists were negative for CTS. Their mean age was 46.92± 7.97 years (range 32-59). The mean BMI in this group was 25.47 ± 4.83 kg/m² (table1).

Mean CSA of the median nerve was found to be 10.29 ± 2.02 mm² (ranging 6.00-16.33) by TM and 10.09 ± 2.08 mm² (ranging 7.00-15.58) by EF.

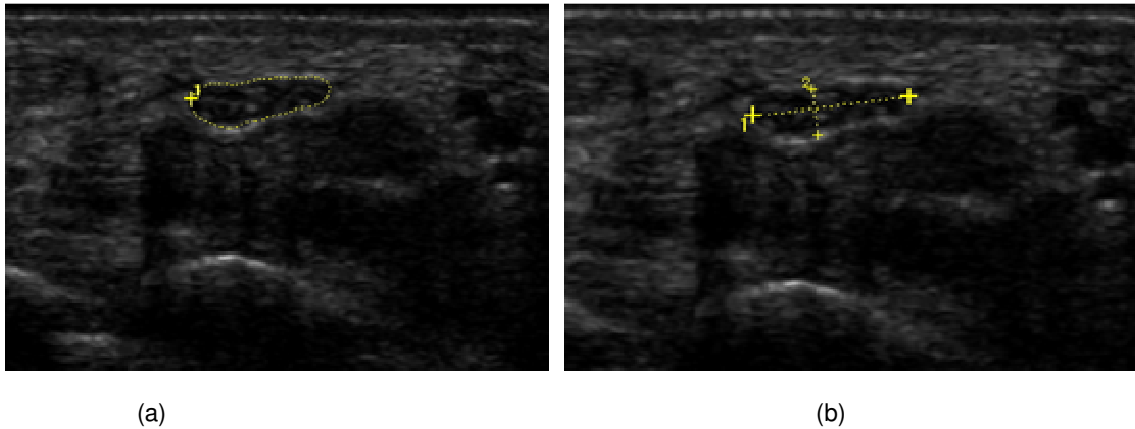


Figure 1. Sonogram of the median nerve in a wrist shows a flattened and a hypo echoic median nerve. (a) The cross-sectional area was 8 mm² using the tracing method. (b) The transverse diameter, AP diameter and cross-sectional area were 58 mm, 17 mm and 7.7 mm², respectively using the ellipsoid formula in a 53-years-old woman whose nerve conduction study of the median nerve was normal.

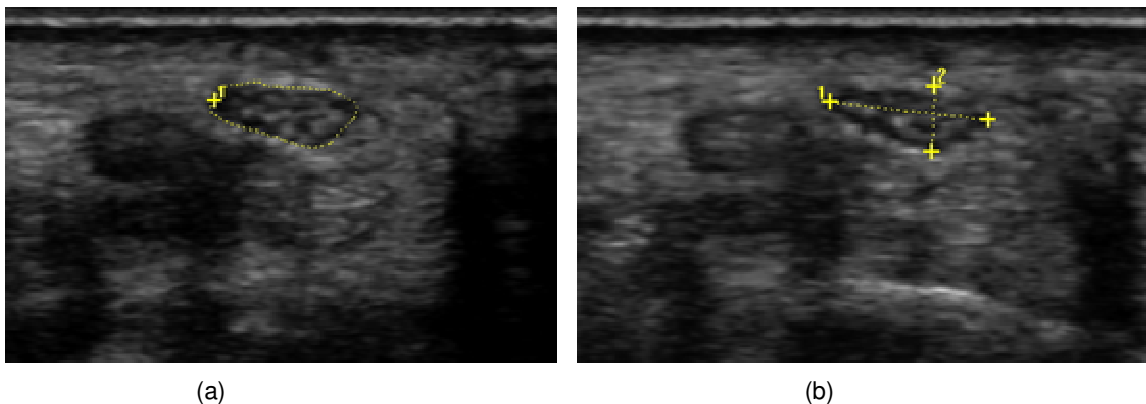


Figure 2. Sonogram of the median nerve in this wrist shows swelling and a hypoechoic median nerve. (a) The cross-sectional area was 11 mm² by the tracing method. (b) The transverse diameter, AP diameter and cross-sectional area were 60 mm, 25 mm and 11.8 mm², respectively by the ellipsoid formula in a 56-year-old man whose nerve conduction study of the median nerve was positive for carpal tunnel syndrome.

No significant differentiation was observed between CSA calculated by TM and by EF ($p = 0.386$).

Both control and study groups

The CSA of the median nerve of the study and control groups were compared using the t-test method. The CSA calculated by TM and EF method were found to be significantly lower in study group than in the control group ($p < 0.001$) (table 2).

We used receiver operating characteristic (ROC) curves to explore the optimal cut-off values of the median nerve's CSA. In this study, the area under the ROC curve for the CSA of the median nerve using TM was 0.93 (CI 95%: 0.87-0.98) (Figure 3). The area under the ROC curve for the CSA of the median nerve using EF was 0.91 (CI 95%: 0.86-0.96) (Figure 4). Using a cut-off value of 9

mm² for TM resulted in a sensitivity of 85.29%, specificity of 90.28%, PPV of 80 % and NPV of 92.7% in diagnosing CTS. With a cut-off value of 9 mm² for EF, the results were 70.59, 87.50, 71.7 and 86% respectively.

DISCUSSION

The chief complaints in all CTS patients were pain and paresthesias. Both the control and CTS patients were examined with the Phalen's and Tinel's tests. The Phalen's and Tinel's tests were positive in 25 % and 11 % of both groups, respectively. Although these tests are classically associated with carpal tunnel syndrome, their actual use in the diagnosis has been less clear. The previous study showed sensitivity estimates of 25% to 75% and specificity estimates of 70% to 90% (Kotevogu and Gülbahce, 2005; Urbano, 2000). In our study, the

Table 2. Ultrasound CSA in the study and the control groups

	Control group	Study group	t-test (p-value)
CSA calculated by TM	6.87 ± 0.93 mm ²	10.29 ± 2.02 mm ²	<0.001
CSA calculated by EF	6.80 ± 0.99 mm ²	10.09 ± 2.08 mm ²	<0.001

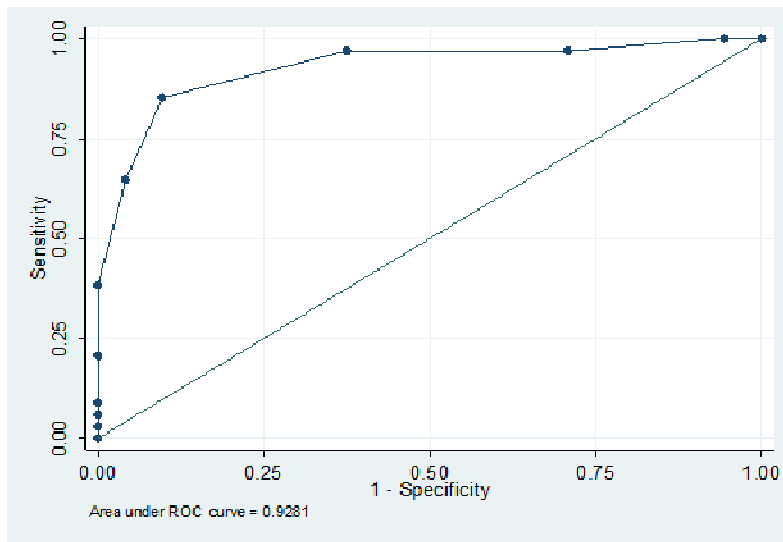


Figure 3. Graph shows ROC curve for the cut-off point of the CSA using TM to diagnose CTS.

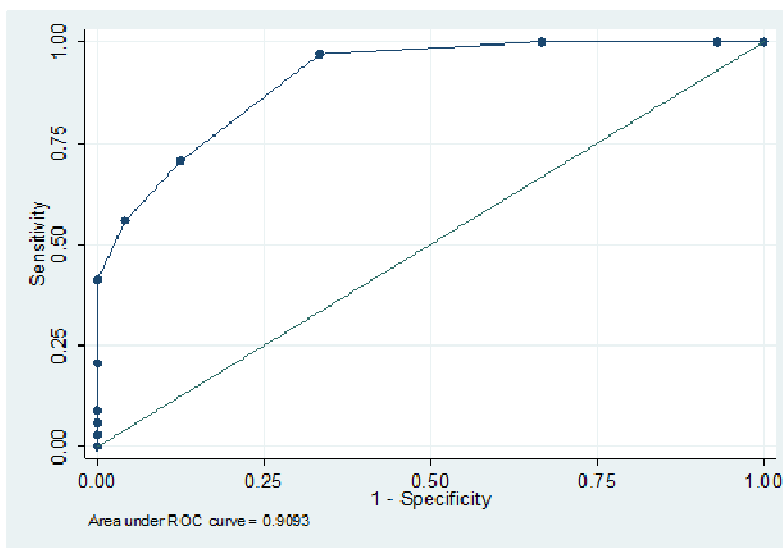


Figure 4. This graph shows ROC curve for the cut-off point of CSA using EF to diagnose CTS.

sensitivity and specificity of the Phalen’s test was 70.59% and 95.83%, respectively. The sensitivity and specificity of the Tinel’s test was 29.41% and 97.22%, respectively.

Current diagnosis of CTS is based on clinical symptoms and confirmed by using NCS. MRI and ultrasound has also been used to confirm the clinical

suspected diagnosis of CTS. Among them, US has potential advantages of being widely available, comfortable, has a relatively lower cost and shorter examination times.

We postulate that CSA cut-off values of the median nerve are smaller than in Caucasian because Asian people have smaller body habitus. The CSA cut-off values of the median nerve which was used in the previous study may not be used in Asian country.

In the majority of previous studies, the ultrasound criteria for the diagnosis of CTS was CSA cut-off values of the median nerve size larger than 9-10 mm² (Duncan et al., 1999; Andrea et al., 2009; Wang et al., 2008; Wong et al., 2004; Kaymak et al., 2008). In our study, the ultrasonographic CTS optimum cutoff value was 9 mm² of the CSA of the median nerve. This result confirmed that no difference in the US cut-off values of the median nerve between the Thai population and other countries.

The previous study showed that the US measurements were highly sensitive (97%) with greater specificity (98%) in the diagnosis of CTS in patients with positive clinical symptoms and NCS (Mohammadi et al., 2009). In 2008, the Renato et al showed the sensitivity and specificity of TM when measuring the CSA were 85% and 92.1%, respectively. The sensitivity and specificity of EF when measuring the CSA were 88.5% and 82.5% (Renato et al., 2008) respectively. Our study showed sensitivity and specificity of TM when measuring the CSA were 85.29% and 90.28%, respectively. The sensitivity and specificity of EF when measuring the CSA were 70.59% and 87.50%, respectively. We found that TM had more sensitivity and specificity than the EF method.

The mean CSA in our control group was 6.89 and 6.87 mm². The majority of previous publications addressed CSA of the median nerve in normal populations as ranging from 7-8 mm² (Duncan et al., 1999; Koyuncuoglu et al., 2005; Diana et al., 2008). This result shows no difference of the mean normal CSA of the medial nerve between the healthy, Thai population and in the others.

CONCLUSION

High sensitivity and specificity of quantitative US assessment in the diagnosis of CTS were confirmed in the patients, when compared with NCS. If NCS was unavailable or uncomfortable in confirming CTS in the patients with clinical symptoms of CTS, US studies may be helpful to diagnose this syndrome. We found no difference of the US cut-off values of the median nerve between the Thai population and the population in other countries. The mean CSA of medial nerve was also not different in the healthy Thai population when compared to the others.

REFERENCES

- Allmann KH, Horch F, Uhl M (1997). MR imaging of the carpal tunnel. *Eur. J. Radiol.* 25:141-145.
- Andrea S, Ethan J, Halpern T (2009). Carpal Tunnel Syndrome Assessment with US: Value of additional cross-sectional area measurements of the median nerve in patients versus healthy volunteers. *Radiol.* 250:171-177.
- Aroori S, Spence R (2008). Carpal tunnel syndrome. *Ulster Med. J.* 77(1):6-17.
- Atroshi I, Gummesson C, Johnsson F, Ornstein E, Ranstam (1999). Prevalence of carpal tunnel syndrome in a general population. *JAMA.* 81(2):153-158.
- Chen P, Maklad N, Redwine M, Zelitt D (1997). Dynamic high resolution sonography of the carpal tunnel. *Am. J. Roentgenol.* 168: 533-537.
- Diana P, Cristina BH, Eugenio MM, Susana SP, Arturo UC, Emilio MM (2008). Validity and usefulness of echography in the carpal tunnel syndrome. *Reumatol. Clin.* 4(3):100-106.
- Duncan I, Sullivan P, Lomas F (1999). Sonography in the diagnosis of carpal tunnel syndrome. *Am. J. Roentgenol.* 173:681-684.
- Kaymak B, Ozçakar L, Cetin A, Candan Ce-tin M, Akinci A, Hasçelik Z (2008). A comparison of the benefits of sonography and electrophysiologic measurements as predictors of symptom severity and functional status in patients with carpal tunnel syndrome. *Arch. Phys. Med. Rehabil.* 89(4):743-748.
- Kotevoglou N, Gülbahçe S (2005). Ultrasound imaging in the diagnosis of carpal tunnel syndrome and its relevance to clinical evaluation. *Joint Bone Spine.* 72:142-145.
- Koyuncuoglu HR, Kutluhan S, Yesildag, Oyar O, Guler K, Ozden A (2005). The value of ultrasonographic measurement in carpal tunnel syndrome in patients with negative electro diagnostic tests. *Eur. J. Radiol.* 56:365-369.
- Mohammadi A, Afshar AR, Masudi S, Etemadi A (2009). Comparison of high resolution ultrasonography and nerve conduction study in the diagnosis of carpal tunnel syndrome: diagnostic value of median nerve cross-sectional area. *Iran J. Radiol.* 6(3):147-152.
- Patterson JD, Simmons BP (2002). Outcomes assessment in carpal tunnel syndrome. *Hand Clin.* 18(2):359-363.
- Renato AS, Claudia AA, Benedito F (2008). Ultrasound features of carpal tunnel syndrome. *Skeletal Radiol.* 37:49-53
- Urbano FL (2000). Tinel's sign and phalen's maneuver: physical signs of carpal tunnel syndrome. *Hosp. Phys.* 7:39-44.
- Wang LY, Leong CP, Huang YC, Hung JW, Cheung SM, Pong YP (2008). Best diagnostic criterion in high-resolution ultrasonography for carpal tunnel syndrome. *Chang Gung Med. J.* 31(5):469-476.
- Wiesler ER, Chloros GD, Cartwright MS, Smith BP, Rushing J, Walker FO (2006). The use of diagnostic ultrasound in carpal tunnel syndrome. *J. Hand Surg. (Am).* 31:726-732.
- Wong SM, Griffith JF, Hui AC, Lo SK, Fu M, Wong KS (2004). Carpal tunnel syndrome: diagnostic usefulness of sonography. *Radiol.* 232(1):93-99.