



## Case Report

# Congenital diaphragmatic hernia in a three-year-old boy: A case report and review of the literature

**\*Oliemen Peterside, Ibinabo Spiff and Felix O Akinbami**

Department of Paediatrics and Child Health, Niger Delta University, Wilberforce Island, Amassoma, Bayelsa State, Nigeria

**\*Corresponding author email address:** docolyemen@yahoo.com.

### ABSTRACT

**Congenital diaphragmatic hernia is uncommon with an incidence of 1 in 2000 to 3500 live births. Less than 20% of cases present outside the neonatal period frequently posing diagnostic challenges. We report a case of congenital diaphragmatic hernia in a three-year-old boy who had previously been treated at other centres without a definitive diagnosis. This is aimed at highlighting the diagnostic and treatment challenges involved in the management of this patient.**

**Keywords:** Congenital, diaphragmatic hernia, late presenting

### INTRODUCTION

A diaphragmatic hernia is defined as a communication between the abdominal and thoracic cavities with or without abdominal contents in the thorax (Narkhede et al., 2014). The most common type is the posterolateral type (Bochdalek) (Morin et al., 1994). The incidence has been reported as 1 in 3,500 live births but increased to 1 in 2000 if still births are included (Morin et al., 1994). Congenital diaphragmatic hernia (CDH) accounts for 8% of all congenital anomalies (Stolar CJ and Dillon P, 2006). The aetiology is unknown, however 2% of cases have been noted to be familial while 15% have associated congenital anomalies (King H and Booker PD, 2005). Most infants with congenital diaphragmatic hernia are born term, two thirds are male and in 90% of cases, the hernia is left sided (Morin et al., 1994). The spectrum of disease of CDH may range from asymptomatic defects not diagnosed in the neonatal period to presentations with immediate respiratory failure presenting in neonatal death (Tsao K and Lally KP, 2012).

Few cases of congenital diaphragmatic hernia have been reported in western (Grillo et al., 1977, Adejuyigbe et al 1998, Adegboye et al., 2002) and Northern Nigeria (Abubakar et al., 2011) but none in Southern Nigeria. This case is herein reported to highlight its existence in this part of the country as well as discuss its diagnostic and management challenges.

### CASE

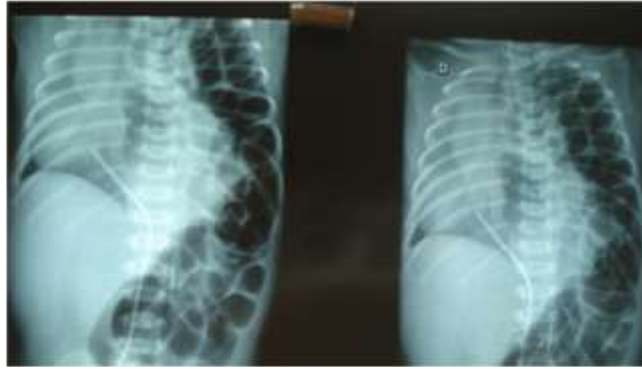
GE, a three-year-old male presented to the children emergency room of the Niger Delta University Teaching

Hospital (NDUTH) with complaints of difficulty with breathing from birth, cough and fever of a month's duration.

Difficulty with breathing started from birth with fast breathing and chest indrawing. It was aggravated by ingestion of feeds. There was no change in body colour and it was not related to activity or change in position. There was no history of easy fatigability. Cough was non-paroxysmal, productive of whitish non-blood stained sputum. It was distressful and worse at night. There was no history of contact with an adult with chronic cough and no night sweats. Fever was high grade, worse at night and temporarily relieved by paracetamol. On systemic review, there was a positive history of weight loss.

His mother had been taking him to traditional healers for local massage. She had also taken him several times to patent medicine dealers who gave unknown drugs which only temporarily relieved the difficulty with breathing. At the onset of cough, she took him to a private hospital where a chest xray and blood tests were done but she was not told the diagnosis. She decided to bring him to the NDUTH as difficulty with breathing worsened.

He was admitted at a private hospital six months prior to present admission for similar illness. His pregnancy was supervised at the NDUTH and was carried to term. It was said to have been uneventful. Pregnancy ultrasound scan was not done. Delivery was supervised at home by a traditional birth attendant and was spontaneous vaginal. He was the last of seven children of parents in a monogamous family, three males and four females. His siblings were all well. His



**Figure 1:** Chest x-ray

mother was a 36-year-old farmer while his father was a 40-year-old carpenter. Both parents had primary education. They all lived in a one bedroom flat with the seven children sleeping in the living room.

On examination, he was in respiratory distress with flaring alar nasi, intercostal and subcostal recession, and was mildly pale. His weight was 11.5kg which was 86% of expected for age. His height was 88cm which was 92.6% of expected for age and his mid upper arm circumference was 13cm which showed borderline nutrition. He had a normal respiratory rate of 36 cycles per minute with an oxygen saturation of 97 to 98%. His anterior chest wall was asymmetrical with bulging on the left hemithorax. There was tracheal deviation to the right. Percussion notes were resonant on the right hemithorax but dull on the left. Bowel sounds were heard over the left hemithorax while rhonchi were heard on the right. Other systems were essentially normal.

A provisional diagnosis of left diaphragmatic hernia was made. Chest x-ray showed presence of bowel loops in the left hemithorax with mediastinal shift to the right (figure 1).

He was nebulized with salbutamol, received tabs prednisolone, antimalarial, and intravenous cefuroxime. He was reviewed by the cardiothoracic surgeon who planned for corrective surgery at a later date. His mother requested to be discharged to enable her source for funds for his surgery but they have not returned till date.

## DISCUSSION

Congenital diaphragmatic hernia is associated with high morbidity and mortality due to two complications namely pulmonary hypoplasia and pulmonary hypertension (Narkhede et al., 1994). Although the mortality in the late diagnosis group is low, the morbidity may be significant (Behrman et al., 1988). Most cases of CDH who present after the neonatal period survive as they have less severe pulmonary hypoplasia (Grillo et al., 1977 and Butler et al., 1993). Late presentation outside the neonatal period as in the index case is present in 2.6 to 20% of all cases between the ages of 1 month to 18 years (Kitano et al., 2005). Other researchers in Nigeria (Grillo et al., 1977; Adejuyigbe et al., 1998; Adegboye et al., 2002 and

Abubakar et al., 2011) and other countries (Chetan et al., 2008; Radovic SV, 2015 and Kim et al., 2011) have also reported cases of late presenting CDH.

Over 90% of patients with CDH are likely to either be diagnosed antenatally or within the first few hours of life (Davenport and Holmes 1995), but this was not the case in the index patient whose mother did not have antenatal ultra-sound scan. Prenatal detection of CDH is said to be uncommon in developing countries like Nigeria due to inadequate facilities (Abubakar et al., 2011). Abubakar et al. (2011) in University of Maiduguri teaching hospital, Nigeria also reported a similar trend among seven cases managed over an eight-year period where 80% of the mothers had abdominal ultrasound scan in pregnancy but no antenatal diagnosis was made. Similarly, Mallikarjunapp and Ashish (2012) in India reported a case of CDH made in a term neonate whose mother had antenatal ultrasound scan which revealed no abnormality. His delivery was also supervised by a traditional birth attendant who probably lacked the skills to identify problems and promptly refer him to a health centre. Late presenting CDH often presents considerable diagnostic challenge because of its varied presentation resulting in diagnostic delay, inappropriate treatment and potentially fatal outcome (Behrman et al., 1988). The index patient had been treated on several occasions by patent medicine dealers and traditional healers and was also managed at a private hospital where the diagnosis was missed even if a chest x-ray was done. Wrong diagnosis of CDH is present in about 25% of cases as pneumonia, pneumothorax, congenital cystic adenomatoid malformation of the lungs, pleural effusion or eventration of the diaphragm (Elhalaby EA and Abo Sikeena, 2002). Abubakar et al. (2011) as well as Lemos et al. (2015) in India also reported similar incidents of repeated treatment for pneumonia at peripheral hospitals among their patients with late presenting CDH.

When diagnosis of CDH is missed in the neonatal period, the patient usually presents later with respiratory events (Elhalaby EA and Abo Sikeena, 2002) like the index patient who presented with recurrent episodes of respiratory distress. They can also present with other gastrointestinal problems or a combination of both (Davenport M and Holmes K, 1995). Respiratory distress in the index patient was

aggravated by ingestion of feeds. This is not surprising as respiratory symptoms in CDH are said to worsen with swallowing of air and food as these results in distension of the intra-thoracic stomach and intestines which further compress the poorly developed pulmonary tissue (Radovic SV, 2015).

Surgical correction is recommended in all cases of CDH to avoid complications (Balanesu et al., 2012) but sadly the index case was lost to follow up before the surgery could be done. This highlights the need for free health care for Nigerian children.

## CONCLUSION

Late presenting CDH usually presents with diagnostic challenges. A high index of suspicion is required for early diagnosis and prompt treatment in order to prevent complications.

## REFERENCES

- Narkhede A, Shrikande DY, Nigwekar P, Nadav S, Kasodariya H (2014). Right sided congenital diaphragmatic hernia: a rare case report. *Int. J. Med. Res. Health Sci.* 3(1): 193 – 194.
- Morin L, Crombleholme TM, D'Alton ME (1994). Prenatal diagnosis and management of fetal thoracic lesions. *Semin Perinatal.* 18: 228 - 253.
- Stolar CJ, Dillon P (2006). Congenital diaphragmatic hernia. In: Grosfeld JL, O'Neil JA, Fonkalsrud EW (Eds) *Pediatric Surgery*. 6<sup>th</sup> ed. Philadelphia: Mosby-Elsevier. Pp932.
- King H, Booker PD (2005). "Congenital diaphragmatic hernia in the neonate". *Cont Edu Anaesth Crit Care Pain.* 5(5): 171 – 174.
- Tsao K, Lally KP (2012). Innovations in the surgical management of congenital diaphragmatic hernia. *Clin. Perinatol.* 39: 363 – 374.
- Grillo AS, Akinyemi OO, Ladipo OA (1977). Congenital diaphragmatic hernia simulating pectus carinatum in a 2-year-old with successful surgical treatment and review of the experience of University College Hospital Ibadan to date. *Nig. J. Med.* 7: 210 – 215.
- Adejuyigbe O, Abubakar AM, Sowande OA, Olayinka OS (1998). Congenital diaphragmatic hernia presenting outside the neonatal period. *Nig. J. Paediatr.* 25: 6 – 9.
- Adegboye VO, Omokhodion SI, Ogunkunle O, Obajimi MO, Brimno AI, Adebo OA (2002). Experience with the management of congenital diaphragmatic hernia at UCH, Ibadan. *Nig. J. Paediatr.* 29: 40 – 46.
- Abubakar AM, Bello MA, Chinda JY, Danladi K, Umar IM (2011). Challenges in the management of early versus late presenting congenital diaphragmatic hernia in a resource poor setting. *Afr. J. Paediatr. Surg.* 8: 29 – 33.
- Behrman L, Stringer D, Ein SH, Shandling B (1988). The late presenting Paediatric Bochdalek hernia: a 20-year review. *J. Pediatr. Surg.* 23(8): 735 – 739.
- Butler MW, Stolar CJ, Altman RP (1993). Contemporary management of congenital diaphragmatic hernia. *World J. Surg.* 17(3): 350 – 355.
- Kitano Y, Lally KP, Lally PA (2005). Congenital diaphragmatic hernia study group. Late presenting congenital diaphragmatic hernia. *J. Pediatr. Surg.* 40(12): 1839 – 1843.
- Chetan G, Sreerag KS, Rathisharmila R, Barath J, Narayanan P, Jagdish S, Vishnu Bath B (2008). Unusual case of congenital diaphragmatic hernia – a case report. *Curr. Pediatr. Res.* 12(1,2): 5 – 7.
- Radovic SV (2015). Late presentation of congenital diaphragmatic hernia – case report. *Srp Arh Celok Lek.* 143(9-10): 604 – 608.
- Kim JM, Couluris M, Schnapf BM (2011). Late presenting left sided Morgagni congenital diaphragmatic hernia in a 9-year-old male. *ISRN Pulmonology* ID 409252, doi: 10.5402/2011/409252.
- Davenport M, Holmes K (1995). Current management of congenital diaphragmatic hernia. *Br. J. Hosp. Med.* 53: 95 – 101.
- Mallikarjunapp B, Ashish SR (2012). Congenita diaphragmatic heria: A case report. *J. Int. Med. Sci. Acad.* 25(4): 247.
- Elhalaby EA, Abo Sikeena (2002). Delayed presentation of congenital diaphragmatic hernia. *Pediatr. Surg. Int.* 18: 480 – 485.
- Lemos SPP, Lemos PVRB, Coelho NAIR, deAreu DM, Feitosa LBR (2015). Congenital diaphragmatic hernia with delayed diagnosis: Report of two cases. *Case Rep. Clin. Med.* 4: 114 – 118.
- Balanesu R, Ulici A, Malureanu D, Stoica I (2012). Morgagni congenital diaphragmatic hernia in a 7-month-old boy. A case report. *J. Ole Chir (Lasi)* 8(3): 291 – 295.

### How to cite this article:

Oliemen et al. (2016). Congenital diaphragmatic hernia in a three-year-old boy: A case report and review of the literature. *Int. Res. J. Basic Clin. Stud.* 4(2):023-025